

CIRSE 2015 – Lisbon
Tuesday, September 29, 2015

Following three great days of lectures, workshops and debates, our visit to Lisbon starts drawing to a close. But fear not: the Scientific Programme Committee and Local Hosts are already working on CIRSE 2016, which will be held in sunny Barcelona from September 10-14!

As one of the most popular cities in Spain, Barcelona offers the ideal infrastructure for large congresses, with excellent accommodation, transport, and many services catering for visitors. The top-notch congress centre hosted us in 2013, and we are delighted to be returning to such a beautifully appointed venue. We cordially invite you to join us – announcements of the programme will follow soon!

Before that, however, there is another day and a half of IR education awaiting you: you'll find some of the highlights listed overleaf. We hope that you'll attend as many as possible!

Barcelona
SEPT
10-14
CIRSE 2016
www.cirse.org

Roesch Lecture: Treatment of CLI – beyond pipe-fitting

Jim A. Reekers (EBIR)

In the early days, interventional radiology focused predominantly on vascular procedures. Only in the last decade has non-vascular IR grown very rapidly, and in many institutions has even started to outflank or replace vascular work. Vascular embolisation technologies have also been booming. At the same time, effective secondary prevention programmes addressing vascular risk factors like smoking, hyperlipidaemia and hypertension are further reducing vascular workloads. In many European countries, intermittent claudication is now a quality-of-life disease for which supervised exercise training (SET) has become the mainstream treatment.

The challenges nevertheless remain unchanged. In fact, both challenges and expectations have increased, as more difficult patients are now increasingly being treated with endovascular techniques. And the goals are no longer limited to improving walking distance, but have reached the level of limb salvage, or sometimes even life salvage.

We are now back where it all started. Interventional radiology was born on January 16, 1964, when Charles Dotter percutaneously dilated a tight, localised stenosis of the superficial femoral artery (SFA) in an 82-year-old woman, with painful leg ischaemia and gangrene, who refused leg amputation. After successful dilation of the stenosis with a guidewire and coaxial Teflon catheters, the circulation returned to her leg. Her pain ceased, she started walking, and three irreversibly gangrenous toes spontaneously sloughed. She

left the hospital on her feet – both of them. The dilated artery stayed open until her death from pneumonia 2.5 years later.

The challenges

Our challenges today are exactly the same as the challenge faced by Dotter in 1964. In our current condensed vascular treatment populations, we are now also mainly confronted with patients with critical limb ischaemia (CLI), often not well-suited for bypass surgery, who need our expertise to save their legs. The growing population of diabetic patients with diabetic foot disease has also become a new challenge. Nevertheless, many things have not changed.

When I started working in this field in 1983, there was one dominant issue in endovascular treatment: how to get it open. I experienced the whole rollercoaster of sentiments that accompanied hot- and cold-tip laser, excimer, endarterectomy and rotablator. These techniques gave rise to great hope, expectations and – let us be honest – joy, but were proven to contribute little to nothing to the opening of lower limb arteries, or to the ultimate outcome. Sub-intimal angioplasty proved to be a very effective and cheap way to open vessels, and made all of these technologies redundant – for a while.

With the introduction of stents in the late 1980s, for a short period hope emerged that these would be the answer to the second issue: how to keep it open. To tackle the problem of

re-occlusion, some of the older and redundant techniques for opening vessels – like laser, endarterectomy and rotablator – were given a second chance. But their use in clinical practice again failed.

About ten years ago, new technologies to keep vessels open following endovascular re-opening began to emerge. Drug-eluting stents and drug-eluting balloons were introduced. A recent meta-analysis of all of these new technologies conducted by our group, however, showed that they completely lack scientific evidence. An abundance of weak, non-controlled and biased studies with irrelevant proxy endpoints were published, often by the same select group of authors. It is interesting to see that in the past thirty years, while we have improved our proxy endpoints – TLR, binary restenosis and LLL – results in terms of limb salvage in CLI, the only endpoint important to patients, has not really changed.

Glorified pipe-fitting

Looking back at my own career in the field of endovascular treatment, I sometimes think that I have been nothing more than a highly-qualified pipe fitter. In a recent (unpublished) meta-analysis of the fate of patients with CLI who were unsuitable or unfit for revascularisation, it was surprising to see that about 50% did not lose their leg and, in most cases, their wounds healed. On the other hand, about 15% of all patients with successful revascularisation, either via endovascular treatment or bypass, will lose their leg for reasons not very well

Don't miss it!

Treatment of CLI: beyond pipe-fitting
Josef Roesch Lecture
Tuesday, September 29, 14:30-15:00
Auditorium 1



Jim A. Reekers
(EBIR)
University of Amsterdam
Amsterdam, Netherlands

Prof. Reekers is Professor of Radiology and Interventional Radiology at the University of Amsterdam.

He played a leading role in securing the recognition of interventional radiology as a medical subspecialty by the UEMS, and is also known for his efforts to introduce evidence-based medicine into IR. A fellow of CIRSE, his long-time involvement with the Society culminated in his presidency from 2007 to 2009. He is currently on the editorial board of CVIR. Prof. Reekers is also a fellow of the Society of Interventional Radiology, and is a member of the European Society of Vascular and Endovascular Surgery and the Dutch Society of Interventional Radiology, of which he was president between 1998 and 2010.

understood. Amputation with open bypass is not rare. Probably only about 35% of all patients with CLI really need revascularisation for limb salvage.

We currently have no idea how to predict outcome after revascularisation treatment for CLI. Measurements like ABI, toe pressure, ankle

>> pressure, TcPo₂ and observation of straight flow to the foot or improved vascularisation of the foot have not been shown to have any predictive value. Because we have no tools to select those patients who will benefit from revascularisation, current practice in the endovascular treatment of CLI is opportunistic: we treat all, based on a debatable definition of CLI, and hope for the best.

Have we identified the correct problem?

Another very interesting observation is that, during the past 20 years, limb salvage of 80-85% after a successful endovascular procedure is consistently reported, irrespective of the technique used. How far can we push the technology? A very recent paper published in the NEJM about drug-eluting balloons in the SFA showed that DEB had better patency at 12 months (still only a disappointing 65% versus 52%), but that this better patency did not translate into a better clinical outcome. Although the patient in this study had (90%) intermittent claudication, a BMI > 30 and no previous lifestyle intervention (supervised exercise training), this shows again that there is no direct relation between patency and outcome, as we often also observe in patients with CLI.

What is the clinical problem we are actually trying to treat? Nobody would treat renal artery stenosis in a patient on dialysis due to chronic kidney function failure in order to improve renal function, or open up a carotid artery to improve flow to the areas of old ischaemia in order to regain brain function. What seems so obvious in other situations has never been a topic of much interest in the context of revascularisation of patients with CLI. If we also take into account that the vast majority of lower limb amputations start with local problems in the foot, the conclusion should be that the foot is the end-organ for patients with CLI. Therefore, the condition of the foot – its remaining functionality – might play a crucial role in outcome after revascularisation. It is probably not just the amount of blood flow to the foot, but also the capability of the foot to use that extra blood to restore tissue nutrition in the foot, that is vital.

Oxygen, needed to prevent change from aerobic metabolism in the tissue of the foot to anaerobic metabolism (causing the symptoms of ischaemia) plays a crucial role. Oxygen

needs no trans-membrane pressure gradient to be transported to the tissue, so oxygen diffusion is independent of blood pressure. It only depends on volume flow. The equation for oxygen concentration in the tissue of the foot depends on two parameters: the amount of oxygen locally available in the blood, and the functionality of microcirculation. There are many ways to improve the amount of oxygen in the foot, such as by increasing blood flow to the foot (revascularisation) or via angiogenesis (stem cell). Increasing oxygen levels in the blood itself by way of hyperbaric oxygen treatment is also a well-known treatment method for ischaemia. But blood oxygen levels can also be increased with simple measures such as improvement of the cardio-pulmonary condition (supervised exercise training and stopping smoking), and treatment of anaemia, which is often seen in patients with chronic kidney failure.

Microcirculation

The other parameter in the equation for tissue oxygen in the foot is the condition of the microcirculation. Although a lot of research has been carried out, especially in the field of diabetic foot disease and ulcer healing, this knowledge has never matured into a clinical tool. Explanations for this are that all of these techniques are very cumbersome, often research-based, and have primarily focused on the skin as target organ for wound healing. Atherosclerosis and diabetic vascular foot disease are an overlapping entity with some disease-specific differences. Impaired wound healing due to the dysfunctional local glucose metabolism in diabetes, and the decreased collateral formation, especially make a difference. Nevertheless, atherosclerosis and diabetic vascular foot disease are both part of generalised vascular disease. In chronic foot disease, it is not only the area of the ulcer, but the whole vasculature of the foot, that is diseased; the area of the ulcer is just the spot acutely in need of an extra supply of oxygen to support ulcer healing.

Here the angiosome theory has misguided us by focusing on the segment where the ulcer is. Of course, increasing the blood flow specifically to that segment is probably good, but it is only part of the story. We need to have more information about the functionality of the microcirculation of the whole foot to be able to judge the burden of vascular disease, and to

better be able to predict outcome, regarding both wound healing and limb salvage.

When we know who will benefit from our procedures, we can improve the outcome of revascularisation by way of better patient selection. In a normal microcirculation of a foot, the vast majority of the blood is shunted. With CLI, the shunting in the microcirculation is reduced to retain as much oxygen as possible to be able to maintain a normal citric acid cycle, which takes place in the mitochondria. Only when there is a shortage of oxygen in the tissue will this cycle become anaerobic, producing lactate. Lactate is responsible for some of the clinical features of CLI, such as pain and loss of motoric functioning.

This ability to adapt to decreasing oxygen levels by reducing the shunting results from vasoconstriction of the arterioles in the microcirculation. This adaptation by way of vasoconstriction can only be seen in a foot that still has some reserve functionality. In a foot unable to adapt with vasoconstriction, any increased inflow will be shunted away and not be used for tissue perfusion. In diabetic foot disease shunting is well known.

How does perfusion angiography play a role here?

Perfusion angiography is a new technique that measures the change in contrast density in the whole foot over time. This time-density curve consists of three elements: 1) the contrast transported through the macrovessels (remaining crural vessels and collaterals) to the foot; 2) the contrast in the microcirculation (arterioles and capillaries); and 3) the contrast in the tissue of the foot.

If there is more inflow, this is represented as a higher curve with a higher peak. Secondly, more blood transported through the crural vessels and collaterals shifts the whole curve to the left. With this information from perfusion angiography, which is instantly available during angioplasty as a post-processing modality, one can calculate the increase in blood flow after angioplasty. Quantification of this blood flow improvement might be a good endpoint for discriminating between an optimal and a sub-optimal PTA procedure. This hypothesis is currently being tested in a European multi-centre trial with clinical endpoints.

An interesting observation we made is that sometimes revascularisation of a tibial artery with poor run-off might steal blood from collaterals, and so decrease actual perfusion of the foot. The ultimate consequence in this situation: refraining from the obvious – opening a crural vessel – might sometimes be even better for the final perfusion result.

The second part of the curve is the representation of the contrast in the tissue. Therefore this is a horizontal line, which will only gradually decrease. This is probably mostly determined by the amount, density and type of contrast medium. Standardisation of contrast medium for perfusion angiography is therefore mandatory to permit data comparisons.

Perfusion angiography can also be used to test the functionality of the microcirculation. This is really greatly promising because this can be used as a direct test to predict outcome and to select patients. Selective vasodilation of the microcirculation will lead to increased microcirculation flow by shunting at the microcirculation level. Quantification of this response to local stimulation is a parameter for the functionality of the microcirculation. This could be termed "capillary flow resistance" of the foot. This option is also currently under investigation.

Moving beyond pipe-fitting

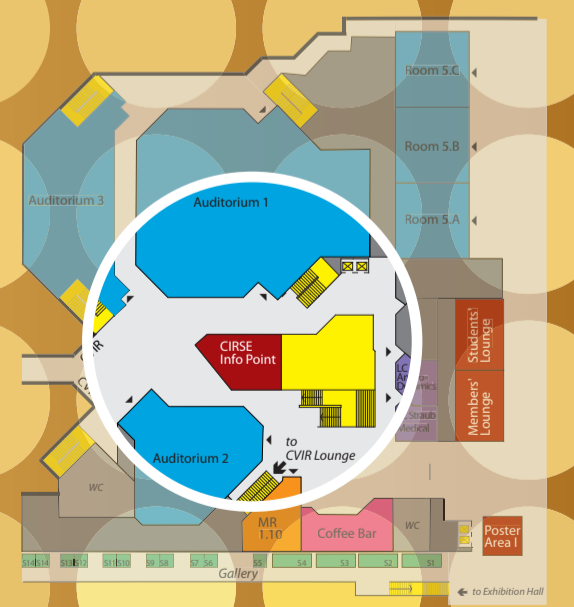
Perfusion angiography paves the way for developing a new way to predict outcome and to look beyond the simple re-opening of vessels. It will teach us about the functionality of the diseased foot and about the disease burden in the microcirculation. It will guide us in making essential decisions about our intervention. It can help in selecting patients who will benefit from revascularisation. However, to make perfusion angiography a success, we need to apply lessons learned from mistakes made with CT-perfusion for stroke, which never matured into a clinical tool because of a lack of standardisation, lack of proper clinical testing, and opportunistic industry introduction.

Perfusion angiography holds huge promise, but the technology still needs more time to become robust enough to be appropriate for use in everyday clinical practice. This is when the pipe fitter will finally become a true clinical doctor.

CIRSE Info Point

Questions about the programme?
Having trouble with the app?
Need help finding a lecture room?

Our friendly staff are on hand to help you with all your congress queries. Call by the **CIRSE Info Point**, conveniently located between Auditoria 1 and 2.



Radioembolisation trials: what is the current evidence?

José Ignacio Bilbao (EBIR)

With the release of data from the SIRFLOX study of radioembolisation (or selective internal radiation therapy; SIRT) with yttrium-90 (Y-90)-labelled resin microspheres, we now have high-quality evidence on the efficacy and safety of this treatment in a large cohort of patients with metastatic colorectal cancer (mCRC) (showing a 31% lower risk of tumours in the liver progressing when SIRT was administered).

Several more large-scale trials of SIRT for mCRC and hepatocellular carcinoma (HCC) will be completed in the next few years, and this will allow for a more evidence-based approach to the use of SIRT. Increasingly, therefore, interventional radiologists will need to analyse this new evidence as it emerges, and must be intimately involved in tumour board decision-making to ensure that SIRT is targeted to the most appropriate patients with mCRC and HCC.

Building the evidence

Involvement of a multidisciplinary team (MDT) is essential in the management of mCRC and HCC. Within these teams, and on tumour boards, the role of the interventional radiologist is becoming increasingly important, and thus, the need to generate level 1 evidence in interventional radiology is growing. In turn, the emergence of data from randomised controlled trials will help define evidence-based practice in interventional oncology.

Because the liver is the predominant site of metastatic disease in CRC [1], radioembolisation is a treatment modality that warrants careful study. SIRT could have potential benefits in a broad group of patients with mCRC and HCC, or when used earlier in the treatment algorithm. SIRT with Y-90-labelled spheres are available as resin microspheres (SIR-Spheres®, Sirtex Medical Limited) or glass microspheres (TheraSphere®, MDS Nordion). SIRT has been administered to thousands of patients over the last two decades, and some small but important trials have been published. However with the presentation of the SIRFLOX study results in 2015, and looking forward to the next few years, the volume of evidence for this treatment will increase dramatically (Fig. 1).

| Study and year | Treatments | N | Median survival | Other endpoints |
|------------------------------------|-----------------|----|-----------------|---|
| First-line | | | | |
| Gray et al. 2001 ² | SIRT + FUDR-HAC | 36 | 39% at 2y | SIRT improved time to liver progression p<0.01 |
| | FUDR-HAC | 34 | 29% at 2y | |
| van Hazel et al. 2004 ³ | SIRT + 5FU/LV | 11 | 29.4 months | TTP: 18.6 months TTP: 3.6 months HR: 0.33, p=0.02 p<0.0005 |
| | 5FU/LV | 10 | 12.8 months | |
| Chemotherapy-refractory | | | | |
| Hendisz et al, 2010 ⁴ | SIRT + 5FU | 21 | 10.0 months | TTLP: 5.5 months TTLP: 2.1 month HR: 0.92, p=0.8 HR: 0.38, p=0.003 |
| | 5FU | 23 | 7.3 months | |

Table 1: Summary of prospective trials with SIRT as first-line or salvage therapy for mCRC

mCRC

Three previously-published randomised studies [2-4] provided the basis of our knowledge on the use of SIRT with Y-90 resin microspheres to treat mCRC. These studies indicated that SIRT has a role in chemotherapy-refractory mCRC, but also delays liver progression and possibly improves overall survival (OS) when added to first-line chemotherapy regimens (Table 1).

A fourth, and considerably larger randomised controlled trial has now been reported, SIRFLOX [5], which greatly enhances our knowledge of the use of SIRT with Y-90 resin microspheres (SIR-Spheres®) in combination with first-line chemotherapy for patients with liver-dominant mCRC. In SIRFLOX, patients were recruited with non-resectable, liver-only or liver-dominant mCRC with no previous chemotherapy for advanced disease. After screening, 530 patients were randomised to receive mFOLFOX chemotherapy (+/- bevacizumab) or mFOLFOX chemotherapy (+/- bevacizumab), plus a single session of SIRT with Y-90 resin microspheres.

The primary endpoint was progression-free survival (PFS) at any site, and there was no significant difference between the groups

(median PFS 10.7 months and 10.2 months in the SIRT group and non-SIRT group, respectively). However, and importantly, assessment of PFS in the liver with a competing risks analysis showed that patients whose treatment included SIRT had a 7.9 month improvement in PFS in the liver from 12.6 to 20.5 months (p=0.002) and a 31% reduced risk (HR=0.69) of the tumours in their liver progressing (Fig. 2). Similar liver resection rates were observed in the two arms of the study.

Y-90 resin microspheres have an average diameter of 30-35 µm (smaller than the particles of other liver-directed therapies such as transarterial chemoembolisation), which allows them to reach intra-tumoural vessels to deliver short-range irradiation [6]. Thus, SIRT has a localised effect that is reflected in the results of the SIRFLOX study. However, why the striking improvements in PFS in the liver did not translate into overall PFS benefits is still intriguing. One possibility (which is currently being investigated) is that the high proportion of patients with synchronous disease (approximately 90%) and primary tumour in-situ (45%) in the SIRFLOX study resulted in extra-hepatic progression irrespective of the progression-status in the liver.

The SIRFLOX study also showed no significant difference in the objective response rate (ORR) between groups, but the complete response rate (6.0% versus 1.9%, p=0.020) and complete response plus partial response rate (78.7% versus 68.8%, p=0.042) in the liver was significantly improved with the addition of SIRT.

The addition of SIRT in the SIRFLOX study had no impact on the duration of chemotherapy and the safety profile was acceptable as predicted from previous data.

OS from the SIRLOX study will be evaluated as part of a pre-planned combined analysis of SIRFLOX and two studies that have recently completed recruitment, FOXFIRE and FOXFIRE Global. These studies combined will include over 1,100 patients and data are expected in mid-2017. The absence of overall PFS benefit in SIRFLOX does not exclude the possibility that OS benefits may be observed in the longer term – for example, the CLOCC study of radio-frequency ablation for patients with colorectal liver metastases showed no OS benefit at 30 months [7], but recently reported long-term

Don't miss it!

**Trials and current evidence in IO
Special Session**
Tuesday, September 29, 10:00-11:00
Room 5.A



José Ignacio Bilbao
(EBIR)
University Clinic of Navarra
Pamplona, Spain

Prof. José Ignacio Bilbao heads the University Clinic of Navarra's Interventional Radiology Department, which he co-established. He has been an active member of CIRSE since its beginnings, and has attended every congress, often presenting award-winning posters and oral presentations or giving invited lectures.

Prof. Bilbao was awarded a Gold Medal at CIRSE 2013. He was the Josef Roesch Lecturer for CIRSE 2010, speaking on TIPS. That same year, he was also awarded the CVIR Editor's Medal for a paper on non-radioactive resin microspheres, of which he was the primary author.

He has served on a number of CIRSE committees over the years, and currently leads CIRSE's Registry for SIR-Spheres Therapy (CIRT).

data that showed a significant difference in OS in favour of RFA plus chemotherapy versus chemotherapy alone [8]. The combined OS data from SIRFLOX/FOXFIRE/FOXFIRE Global are eagerly anticipated and will further enhance our knowledge of the potential benefits of SIRT.

Another randomised study involving approximately 350 patients with mCRC (EPOCH) is assessing the use of SIRT when added to second-line chemotherapy versus second-line chemotherapy alone. The primary endpoint is PFS (Fig. 1; ClinicalTrials.gov identifier: NCT01483027).

HCC

A similar growth in the evidence base and drive to a greater evidence-based approach is occurring with SIRT for HCC.

ENRY provided survival data in a large population (n=325) who had received Y-90 resin microspheres, and showed that factors such as ECOG performance status and tumour burden influenced survival after treatment with SIRT [9].

Recently, a pilot randomised trial (SIRTACE) suggested that SIRT may be an alternative to TACE for patients with unresectable HCC, as a single session of SIRT with Y-90 resin microspheres had a similar impact on ORR and HRQoL as multiple sessions of TACE [10].

The full reporting of much larger randomised controlled trials of SIRT in HCC (possibly as early as 2016) will greatly increase the evidence base for this treatment. Ongoing studies (all with survival as the primary endpoint) include (Fig. 1):

- The SORAMIC trial, which compares sorafenib alone with SIRT followed by sorafenib in 375 patients with advanced HCC [11].
- The SARAH trial compares sorafenib with SIRT in at least 400 patients with advanced HCC [12].
- The SIRveNIB trial, which also compares sorafenib with SIRT in approximately 360 patients with locally-advanced HCC (ClinicalTrials.gov identifier: NCT01135056).

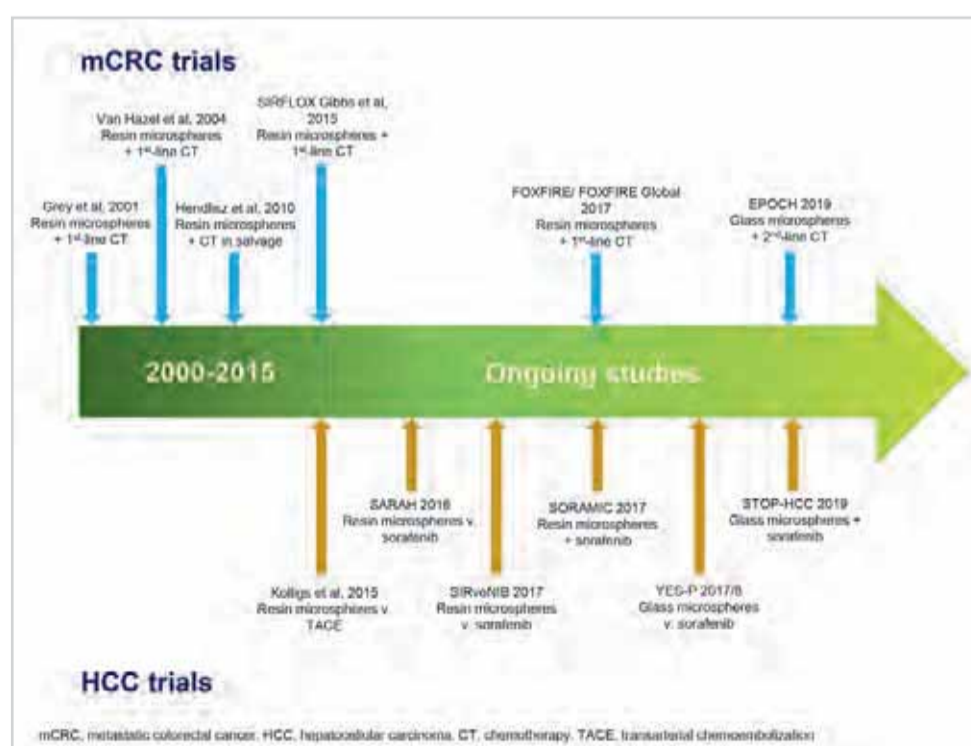


Fig. 1: Randomised controlled trials of SIRT for mCRC or HCC

- >>
- STOP-HCC, which compares sorafenib alone with SIRT plus sorafenib in approximately 400 patients with unresectable HCC (ClinicalTrials.gov identifier: NCT01556490).
 - SIRT is also being compared with sorafenib for the treatment of patients with unresectable HCC and blockage of the portal vein, in the YES-P trial. An enrolment of just under 350 patients is planned (ClinicalTrials.gov identifier: NCT01887717).

Implications of a growing evidence base

With the release of data from the SIRFLOX trial [5], high quality, level 1 evidence can now be used to inform the use of SIRT with Y-90 resin microspheres for the treatment of mCRC at an earlier stage.

The next few years are set to see an even greater volume of evidence on SIRT use in mCRC and HCC. SIRT has been available for several years, but with the new data emerging on this therapy option, our challenge as interventional radiologists will no longer be the uncertainties in the literature, but will be to interpret the wealth of evidence in order to deliver SIRT optimally to patients who could most benefit.

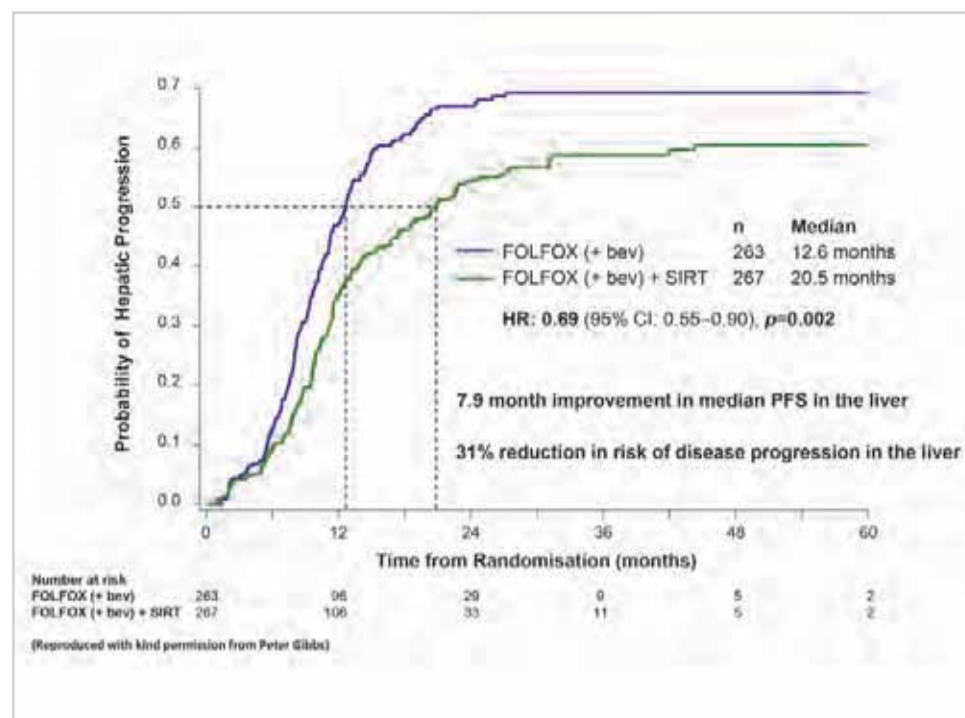


Fig. 2: PFS in the liver (cumulative incidence of liver progression) in the SIRFLOX trial. Reproduced with kind permission from Peter Gibbs.

References:

1. Manfredi S, Lepage C, Hatem C, Coatmeur O, Faivre J, Bouvier AM. Epidemiology and management of liver metastases from colorectal cancer. *Ann Surg* 2006;244:254-9
2. Gray B, Van Hazel G, Hope M, et al. Randomised trial of SIR-Spheres plus chemotherapy vs. chemotherapy alone for treating patients with liver metastases from primary large bowel cancer. *Ann Oncol* 2001;12:1711-20
3. Van Hazel G, Blackwell A, Anderson J, et al. Randomised phase 2 trial of SIR-Spheres plus fluorouracil/leucovorin chemotherapy versus fluorouracil/leucovorin chemotherapy alone in advanced colorectal cancer. *J Surg Oncol* 2004;88:78-85
4. Hendlitz A, Van den Eynde M, Peeters M, et al. Phase III trial comparing protracted intravenous fluorouracil infusion alone or with yttrium-90 resin microspheres radioembolization for liver-limited metastatic colorectal cancer refractory to standard chemotherapy. *J Clin Oncol* 2010;28:3687-94
5. Gibbs P, Heinemann V, Sharma NK, et al. SIRFLOX: Randomized phase III trial comparing first-line mFOLFOX6 ± bevacizumab (bev) versus mFOLFOX6 + selective internal radiation therapy (SIRT) ± bev in patients (pts) with metastatic colorectal cancer (mCRC). *J Clin Oncol* 2015;33 (suppl.):A3502
6. Sangro B, Inarrairaegui M. Radioembolization for hepatocellular carcinoma: evidence-based answers to frequently asked questions. *J Nucl Med Radiat Ther* 2011;2:1000110
7. Ruers T, Punt C, Van Coevorden F, et al. Radiofrequency ablation combined with systemic treatment versus systemic treatment alone in patients with non-resectable colorectal liver metastases: a randomized EORTC Intergroup phase II study (EORTC 40004). *Ann Oncol* 2012;23:2619-26
8. Ruers T. Radiofrequency ablation (RFA) combined with chemotherapy for unresectable colorectal liver metastases (CRC LM): long-term survival results of a randomized phase II study of the EORTC-NCRI CCSG-ALM Intergroup 40004 (CLOCC). *J Clin Oncol* 2015;33 (suppl.):A3501
9. Sangro B, Carpanese L, Cianni R, et al. Survival after yttrium-90 resin microsphere radioembolization of hepatocellular carcinoma across Barcelona clinic liver cancer stages: a European evaluation. *Hepatology* 2011;54:868-78
10. Kolligs FT, Bilbao JI, Jakobs T, et al. Pilot randomized trial of selective internal radiation therapy vs. chemoembolization in unresectable hepatocellular carcinoma. *Liver Int* 2015;35:1715-21
11. Ricke J, Bulla K, Kolligs F, et al. Safety and toxicity of radioembolization plus Sorafenib in advanced hepatocellular carcinoma: analysis of the European multicentre trial SORAMIC. *Liver Int* 2015;35:620-6
12. Vilgrain V, Abdel-Rehim M, Sibert A, et al. Radioembolization with yttrium-90 microspheres versus sorafenib for treatment of advanced hepatocellular carcinoma (SARAH): study protocol for a randomised controlled trial. *Trials* 2014;15:474

Don't miss the Morbidity & Mortality Conference tomorrow at 11:30 in Auditorium 1



The Morbidity & Mortality Conference is an important part of each CIRSE Congress, analysing interventional radiology cases which have led to complications or deaths that could have been avoided. This provides a valuable learning experience for attendees, who can benefit from the experience of their colleagues, allowing them to avoid the same pitfalls.

Once presented with a case, audience members will be asked to vote on their preferred course of action – allowing you to see how you might have fared when faced with that difficult decision.

Don't miss this golden opportunity to learn from someone else's mistakes

Lymphatic malformations of the orbit

Alex Barnacle

Sclerotherapy is well recognised as a first-line treatment for most lymphatic malformations (LMs). These slow-flow malformations occur most commonly in early childhood, usually presenting as subcutaneous cysts in the neck, trunk or less frequently in the extremities. Rarely, they occur in locations such as the mesentery, genitourinary tract and orbit. As those radiologists with an interest in vascular anomalies will know, such lesions are often poorly understood by the specialists to whom they present and patients can struggle to get a definitive diagnosis or appropriate treatment.

LMs of the orbit are rare. They are known to oculoplastic surgeons as 'lymphangiomas' and are recognised as lesions that are difficult to resect and highly prone to complications and recurrence. Sclerotherapy has led to a paradigm shift in the management of this condition, with percutaneous sclerotherapy replacing high-risk surgical intervention entirely and showing a dramatic improvement in patient outcomes.

As with other vascular malformations, orbital LMs usually present in childhood, although small lesions can present late after a spontaneous intralesional bleed. They tend to be isolated, unilateral lesions, though a subset is associated with micro-cystic lymphatic malformations of the face. Orbital LMs are typically macro-cystic and have a characteristic imaging appearance, with large thin-walled cysts, fluid-fluid levels and little enhancement. They are usually centred in the posterior orbit with both intraconal and extraconal components. They tend to wrap around the optic nerve complex, which explains why oculoplastic surgeons are often reluctant to intervene.

Orbital LMs cause mass effect within the orbit, leading to orbital expansion if they are present from an early age, deformity of the globe and proptosis. Proptosis causes stretching of the optic nerve, which is extremely painful when an acute bleed causes rapid expansion of the cysts. Stretching of the optic nerve and raised orbital pressures lead to optic neuropathy and visual loss over time. In young children, vision may fail to develop normally at all. The condition is exacerbated by recurrent intralesional bleeds and infection. In severe cases, patients are plagued by severe chemosis (inflammation and swelling of the conjunctiva), disfigurement and pain, as well as complete visual loss (Fig. 1).

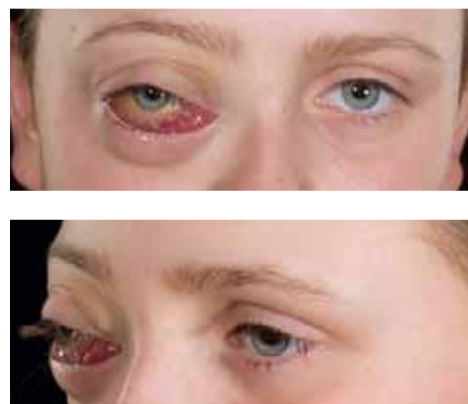

Fig. 1: 13-year-old female presenting with a lymphatic malformation of the right orbit. No previous treatment.

Percutaneous sclerotherapy is well established as a first-line treatment for lymphatic malformations elsewhere in the body, using a variety of sclerosing agents, including sodium tetradecyl sulfate (STS), ethanol, OK-432 (Picibanil™), bleomycin and doxycycline [1]. A few centres have reported the use of percutaneous sclerotherapy in the management of orbital LMs with a variety of sclerosing agents and techniques, and the results have been extremely promising.

In our centre, STS and bleomycin are the sclerosing agents of choice. In our experience, dilute STS (1.5%) is reliably effective in macro-cystic lesions and bleomycin is the drug of choice for micro-cystic lesions and those with a vascular component. Other centres rely almost exclusively on bleomycin. The sclerotherapy technique must be meticulous and there is a steep learning curve involved. The operator must ensure that there are no vascular connections between the lesion and the cavernous sinus or ophthalmic artery and other structures. This is best done with biplane DSA contrast 'cystography' immediately prior to injection of the sclerosant. Typically, the malformation can be well visualised with ultrasound and accessed via an upper lid percutaneous approach. Most cysts communicate and so only the largest cysts need to be injected. Only very small aliquots of sclerosant should be instilled at each sitting. Even with bleomycin, post-sclerotherapy swelling can be severe and patients, especially children, need to be warned about this. Orbits that are actively inflamed at the time of treatment may take several weeks to recover from the first treatment, and patience, as well as courage, is required. Most operators would recommend waiting for an acute episode of proptosis to settle before commencing treatment.

All patients should be under the shared care of an expert ophthalmology team in the treating centre, to confirm the diagnosis, treat the secondary effects of the condition, monitor visual acuity pre- and post-treatment, and to manage complications. Temporary third-nerve palsies are common in the first few hours to days after sclerotherapy. In expert hands, direct optic nerve damage appears to be rare. Most commonly, severe post-procedure swelling may cause raised intraocular pressure requiring active medical management (steroids, acetazolamide) or surgical decompression (lateral canthotomy).

In experienced centres, sclerotherapy is proving highly effective in terms of lesion shrinkage (Fig. 2) and improvement in proptosis (Fig. 3). This may take several treatments over a period of some months, and it is rare for the malformation to resolve completely on imaging, though clinical recurrence rates seem low so far. Detailed visual acuity outcomes have only been documented in the two largest published series, but in both the improvement in visual acuity post-treatment was statistically significant [2, 3]. In our series, this was an unexpected outcome, the service having been set up primarily to relieve pain, infection and mass effect associated with the condition. It had been assumed that any associated visual

loss at presentation would be permanent. Improvement in vision is probably due to a number of factors such as decreased distortion of the globe, decreased ptosis, improvement in alignment of the globe within the orbit (and thus reduced diplopia), and expert ophthalmological care in terms of corrective prescription lenses and patching for children.

For both interventional radiologists and ophthalmologists charged with managing this complex condition, sclerotherapy is proving to be a highly reliable and effective treatment option. Sclerotherapy is not a procedure well known to ophthalmologists and so this treatment option must be championed. It has changed the way this condition is managed and given patients confidence in a good outcome for what was previously an incurable and devastating disease.

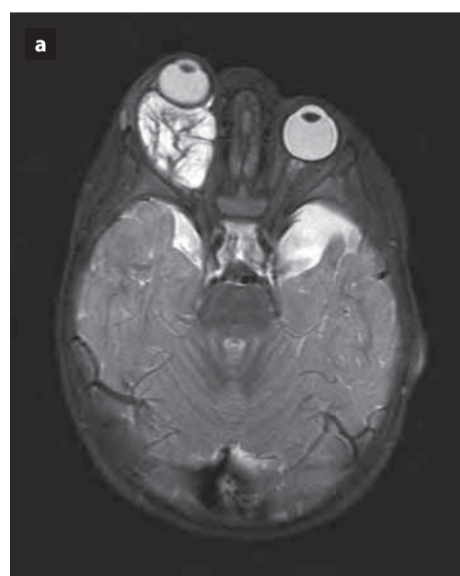


Fig. 2: T2-weighted axial MRI images of a one-year-old child with a lymphatic malformation of the right orbit a) pre-treatment and b) after five sclerotherapy procedures.

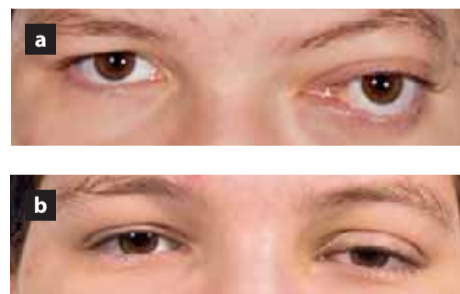

Fig. 3: 14-year-old female with a lymphatic malformation of the left orbit a) pre-treatment and b) post-sclerotherapy.

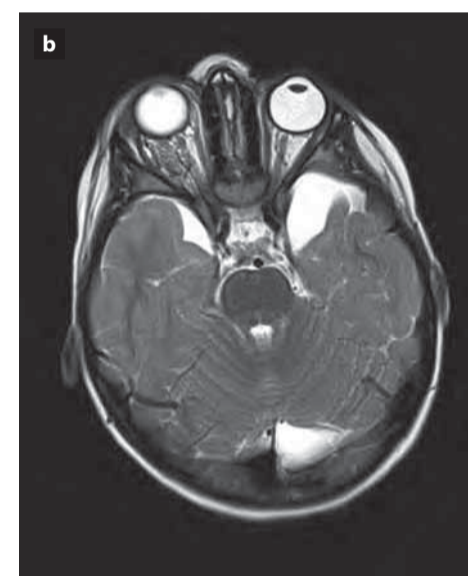
Don't miss it!

Paediatric IR – expand your horizons
Hot Topic Symposium
Tuesday, September 29, 15:00-16:00
Auditorium 1



Alex M. Barnacle
Great Ormond Street Hospital
London, UK

Dr. Barnacle is a full-time consultant in paediatric interventional radiology at Great Ormond Street Hospital, where she is the lead radiologist for the vascular anomalies service. Other areas of expertise include the management of paediatric renal stones, thrombolysis and musculoskeletal interventions in children. Dr. Barnacle is a member of several professional societies, including the Society of Pediatric Interventional Radiology, the British Society of Interventional Radiology and CIRSE. Dr. Barnacle also co-directs "Vascular Anomalies: A clinical approach", a biannual conference in the UK.



- References:**
1. Cahill AM, Nijs E, Ballah D, et al. Percutaneous sclerotherapy in neonatal and infant head and neck lymphatic malformations; a single centre experience. *J Pediatr Surg* 2011;46:2083-95
 2. Hill RH, Shiels WE, Foster JA, et al. Percutaneous drainage and ablation as first line therapy for macrocystic and microcystic orbital lymphatic malformations. *Ophthalmol Plast Reconstr Surg* 2012;28:119-25
 3. Barnacle AM, Theodorou M, Maling SJ, et al. *Br J Ophthalmol* 2015 Jun 17. Pii: bjophthalmol-2015-306657. doi: 10.1136/bjophthalmol-2015-306657 [Epub ahead of print]



CIRSE meets China



The *CIRSE meets...* programme has proved to be an important platform for establishing and strengthening the relations between CIRSE and its distinguished Group Members – the national societies in the field of interventional radiology.

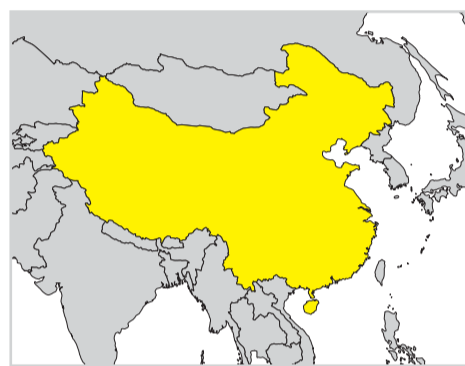Joining us this year is China. This vast and dynamic country has acquired a wealth of clinical data on a number of promising IR procedures, and representatives of the Chinese Society of Interventional Radiology (CSIR) will join us today to share their experiences.

Background

Interventional radiology (IR) was introduced to China during the 1980s in conjunction with China's policy of economic reform and opening up. IR was immediately accepted and welcomed by most radiologists after its introduction. The first national interventional radiology meeting was held in 1986 in Weifang City, Shandong Province, and more than 100 radiologists, residents and graduate students participated. This was a landmark event announcing the advent of IR in China. Four years later, the Chinese Society of Interventional Radiology (CSIR) was founded, and Dr. Lin was elected as the first CSIR president at the first national CSIR meeting in Hangzhou, Zhejiang Province, in

1990. The national meeting of CSIR was held every 4 years in the early years, and then every 2 years, and will become annual meeting from 2015 onwards. A total of eleven national CSIR meetings have been held. The most recent CSIR biennial meeting was held in Changsha in 2014, with more than 3,000 IRs participating.

Currently, there are approximately 5,000 full-time interventional radiologists across the country, meaning that CSIR has become the third largest IR society in the world, after SIR and CIRSE. Most non-coronary IR procedures are performed by radiologists, including various vascular and non-vascular interventions, neurointerventions, etc. However, turf



battles have become intense since the 1990s, especially in the field of vascular interventions and neurointerventions. Nevertheless, we have not only survived, but also won the battles in many hospitals. One of major reasons we manage to hold our ground is that CSIR has been a strong advocate for interventional radiology to be a more clinical specialty. Currently, over 70% of IR departments in China have their own dedicated inpatient wards. Some of them have become a hybrid department of interventional radiology with other specialties, such as vascular surgery.

Many IR pioneers have contributed to the growth of CSIR, including overseas inter-

ventional radiologists, who made important contributions to the practice of IR in China, especially during the early years. To commend such great contributions, the awards of CSIR Lifetime Achievement and CSIR Honorable Member have been established, respectively. So far, twelve Chinese IR pioneers and eight foreign interventional radiologists have been awarded.

Today, three representatives, including Distinguished Fellow Gao-Jun Teng, will describe their findings in their respective fields.

Join us in Auditorium 8 for this exciting event!

Tuesday, September 29

10:00-11:00

CM 2605 CIRSE meets China

Moderators: A.-M. Belli (London/UK), W.-J. Jiang (Beijing/CN)

2605.1 Percutaneous transhepatic portosystemic shunt

H. Wang (Guangzhou/CN)

2605.2 Stent loaded with ¹²⁵I seeds in malignancies – from bench to bedside

G.-J. Teng (Nanjing/CN)

2605.3 Hybrid intervention for complex cerebrovascular disease

W.-J. Jiang (Beijing/CN)

ESIR 2015 Courses

Register now for the ESIR autumn courses!

Don't miss your chance to benefit from the first-rate educational programme offered by the European School of Interventional Radiology.

Critical Limb Ischaemia – Diagnosis, Treatment and Parameters for Success

Expert Course

Amsterdam (NL), October 16-17

Prostate Embolisation

Expert Course

Milan (IT), October 29-30

Effective Hepatocellular Carcinoma (HCC) Treatments – Advanced Local Therapies

Expert Course

Lausanne (CH), November 13-14

DVT & Pulmonary Embolus

Fundamental Course

Dublin (IE), November 27-28

The Future of Image-Guided Tumour Ablation – Targeting Techniques and High-End Clinical Strategies

Expert Course

Innsbruck (AT), December 11-12



CIRSE foundation

For more information, please visit

www.cirse.org/esir2015

Fundamental courses are suitable for preparing for EBIR (European Board of Interventional Radiology)

TIPS for refractory ascites and variceal bleeding

Élia Coimbra

Transjugular intrahepatic portosystemic shunt (TIPS) is one of the treatments available to control the complications of portal hypertension. Portal hypertension is defined as portal venous pressure >10 mmHg, or a portal venous pressure gradient of >5 mmHg, and may lead to complications such as variceal bleeding and ascites. Liver cirrhosis is the most common cause of portal hypertension.

TIPS, by creating a low-resistance shunt between the hepatic vein and the intrahepatic portion of the portal vein, and keeping it patent with an expandable covered metal stent, allows the blood to return to the systemic circulation at low pressure. The ability of TIPS to function like a surgical side-to-side portacaval shunt without requiring general anaesthesia and major surgery led to its rapid acceptance into clinical practice [1]. TIPS is a procedure performed under fluoroscopy and/or ultrasound guidance, by an interventional radiologist (IR), and it has a fairly steep learning curve.

The only curative treatment for portal hypertension and cirrhosis is liver transplant. We believe that this type of procedure should be performed in reference centres where a multidisciplinary approach is possible, and where experienced IRs can train others.

What is refractory ascites?

Diuretic-resistant ascites is usually associated with advanced cirrhosis, marked neurohumoral activation and low urinary excretion of sodium, despite maximal tolerated doses of diuretics. The development of diuretic resistance is most often due to progression of liver disease, however, it can also be due to other complications of cirrhosis, such as hepatocellular carcinoma and portal vein thrombosis, which must be ruled out.

The 2-year survival rate of all patients with cirrhosis after the development of ascites is approximately 50% [2, 3]. By comparison, survival in patients with diuretic-resistant ascites is 50% at 6 months and 25% at 1 year [4].

Diuretic-resistant ascites in patients with cirrhosis is present if one of the following criteria is fulfilled in the absence of therapy with NSAIDs [5] (which can interfere with diuretic responsiveness):

- inability to reduce ascites despite confirmed adherence to the dietary sodium restriction and the administration of maximum tolerable doses of diuretics;
- rapid re-accumulation of fluid after therapeutic paracentesis, despite adherence to a sodium restricted diet; and
- the development of diuretic-related complications such as progressive azotemia,

hepatic encephalopathy, or progressive electrolyte imbalances.

Diuretic-resistant ascites in patients with cirrhosis must be differentiated from malignant ascites due to peritoneal carcinomatosis, Budd-Chiari syndrome or malignant chylous ascites.

Liver transplantation is the only definitive treatment for refractory ascites.

A guideline from the American Association for the Study of Liver Diseases (2009) recommends that TIPS should be considered only in patients who are intolerant of repeated large volume paracentesis [6].

TIPS has also been validated as an effective and safe treatment for ascites secondary to portal hypertension [7].

A recently published case-control study [8] concluded that TIPS appears to be beneficial compared to serial paracentesis in terms of intermediate/long-term overall survival, without significantly worsening short-term mortality, suggesting a potential earlier role in properly selected patients, when conservative medical managements fails.

Acute variceal haemorrhage

As a consequence of portal hypertension, this can be recurrent or refractory to therapy. Variceal bleeding is one of the leading causes of death in patients with cirrhosis. After the first episode, the risk of recurrent bleeding in the next 2 years is 50-80% [9].

Several treatments are available for the management of acute variceal haemorrhage. These can be broadly grouped into treatments that address the local bleeding site, and those that reduce portal pressure. Neither treatment available for variceal haemorrhage is optimal. Firstly, because these fail to uniformly achieve homeostasis, and secondly, due to the inability to arrest progression of cirrhosis or prevent liver failure. The goal of treatment of active variceal haemorrhage is to stop initial bleeding, prevent recurrent bleeding and minimise treatment-associated morbidity and mortality. Endoscopic and pharmacologic treatments are the first-line therapies.

The early placement of TIPS can lead to good outcomes in select patients when performed by experienced IRs, in institutions where TIPS is readily available [10].

The definition of "failure of endoscopic treatment" remains controversial; we consider failure to be the recurrence of variceal haemorrhage despite at least two sessions of endoscopic treatment performed no more than two weeks apart.

Multiple series have demonstrated the efficacy of TIPS for uncontrolled oesophageal variceal haemorrhage despite emergent endoscopic and pharmacologic treatment in patients who are poor candidates for urgent surgery [11-12]. Few studies have compared TIPS to surgery in the management of refractory haemorrhage in patients who are good surgical candidates.

A 2009 guideline issued by the American Association for the Study of Liver Diseases concluded that TIPS or a distal splenorenal shunt were similarly effective in the prevention of re-bleeding, in patients who failed medical therapy, based upon the results of a controlled trial [6, 13]. Thus, it may be reasonable to consider the available expertise and the patient's individual circumstances. TIPS is also a useful temporising measure in those awaiting liver transplantation.

Contraindications to TIPS

Absolut contraindications to TIPS include heart failure, severe tricuspid regurgitation, severe pulmonary hypertension, multiple hepatic cysts, uncontrolled systemic infection or sepsis or unrelieved biliary obstruction. Relative contraindications are central hepatoma, portal vein thrombosis and severe coagulopathy.

Complications

TIPS insertion can be associated with a number of complications, some of which may be fatal. It is therefore essential for all who use this procedure to be aware of the clinical spectrum of TIPS-related complications and their management. There are technical complications, complications related to creation of the shunt, and unique TIPS-related complications. Liver failure and encephalopathy (30%) are the more frequently expected.

The future

Since it was proven that TIPS is beneficial in cases of refractory ascites and variceal bleeding, the next step is to proceed to better selection of patients and optimising the timing of the procedure's execution. In fact, studies have shown that TIPS must be performed earlier in case of variceal bleeding [14].

But what about refractory ascites?

The benefits of TIPS in other clinical situations, such as hepatorenal syndrome, Budd-Chiari syndrome, hepatic hydrothorax, portal hypertensive gastropathy and hepatic sinusoidal obstruction syndrome, remain unclear. Studies predicting post-TIPS encephalopathy are important in order to help guide patient selection [15].

Don't miss it!

Venous Forum IV: Portal hypertension
Special Session

Wednesday, September 30, 08:30-09:30

Auditorium 6



Élia Coimbra
Centro Hospitalar
Lisboa Central
Lisbon, Portugal

Dr. Élia Coimbra is the head of the Interventional Radiology Department in the Hepato-Biliary Centre of Hospital Curry-Cabral CHLC Lisbon. She is the Chairperson of the Local Host Committee for CIRSE 2015, and previously served on the Local Host Committee for CIRSE 2012. Dr. Coimbra has contributed to several scientific posters exhibited at CIRSE events, including on hepatic vein embolisation after portal vein embolisation, and on IVC filters above renal veins.

References:

1. Boyer TD. Transjugular intrahepatic portosystemic shunt: current status. *Gastroenterology* 2003;124:1700
2. Ginés P, Quintero E, Arroyo V et al. Compensated cirrhosis: natural history and prognostic factors. *Hepatology* 1987; 7:122
3. D'Amico G, Morabito A, Pagliaro L, Marubini E. Survival and prognostic indicators in compensated and decompensated cirrhosis. *Dig Dis Sci* 1986;31:468
4. Borjes P, Garcia Compean D, Michel H et al. The treatment of refractory ascites by the LeVeen shunt. A multi-centre controlled trial. *J Hepatol* 1986;3:212
5. Runyon BA. Refractory ascites. *Semin Liver Dis* 1993; 13:343
6. Boyer TD, Haskal ZJ. American Association for the Study of Liver. The Role of Transjugular Intrahepatic portosystemic shunt (TIPS) in the Management of Portal Hypertension: update 2009. *Hepatology* 2010;51:306
7. Rossle M, Gerbes AL. TIPS for the treatment of refractory ascites, hepatorenal syndrome and hepatic hydrothorax: a critical update. *Gut* 2010;59:988-1000
8. Gaba RC, Parvianian A, Casadaban LC, Couture PM, Zivin SP, Lakhoo J, Minocha J, Ray JR CE, Knuttinen MG, Bui JT. Survival benefits of TIPS versus serial paracentesis in patients with refractory ascites: a single institution case-control propensity score analysis. *Clinical Radiology* 2015; 70, 51-57
9. Monesillo A, Martínez-Lagares F, Ruiz-del-Arbol L, et al. Influence of portal hypertension and its early decompression by TIPS placement on the outcome of variceal bleeding. *Hepatology* 2004; 40:793
10. Pagliaro L, D'Amico G, Luca A, et al. Portal Hypertension: diagnosis and treatment. *J Hepatology* 1995; 23 (suppl I):36-44
11. Jalan R, John TG, Redhead DN, et al. A comparative study of emergency transjugular intrahepatic portosystemic stent-shunt and esophageal transection in the management of uncontrolled variceal hemorrhage. *Am J Gastroenterol* 1995; 90:1932
12. Bañares AJ, Casado M, Rodríguez-Láiz JM, et al. Urgent transjugular intrahepatic portosystemic shunt for control of acute variceal bleeding. *Am J Gastroenterol* 1998;93:75
13. Henderson JM, Boyer TD, Kutner MH, et al. Distal splenorenal shunt versus transjugular intrahepatic portal systematic shunt for variceal bleeding: a randomized trial. *Gastroenterology* 1996;111:138
14. Garcia-Pagan JC, Pascoli M, Caca K, Laleman W, Bureau C, Appenrodt B, Luca a, Zipprich A, Abroades JG, Nevens F, Vinel JP, Saverbrunch T, Bosh J. Use of early-TIPS for high risk Variceal Bleeding: results of a pos-RCT surveillance study. *J of Hepatology* 2013; 58
15. Berlioux P, Robic MA, Poirson H, Metivier S, Otal P, Barret C, Lopez F, Péron JM, Vinel JP, Bureau C. Pre-Transjugular Intrahepatic Portosystemic shunts(TIPS) Prediction of Post-TIPS Overt Hepatic Encephalopathy: The Critical Flicker Frequency is More Accurate than Psychometric Tests. *Hepatology* 2014;59,2

Cardiovascular and Interventional Radiological Society of Europe

Don't forget you can submit your session evaluations online!

The CIRSE Society app offers paperless session evaluation – and not just during the session itself!

Session evaluation is a pre-requisite for obtaining CMEs for congress attendance. It also helps us refine the programme for next year.


Be sure to submit in time!



New! Use the CIRSE App to search for exhibitors by product category



Available for iOS and Android



INNOVATION | EDUCATION | INTERVENTION

ESIRonline

A WEALTH OF IR LEARNING

CIRSE is more than just an annual congress – the society strives to facilitate and encourage continuing medical education all year round.

One such service is ESIRonline – the world's largest educational database for IR.

Its 8,000 presentations will soon be expanded to include the presentations from CIRSE 2015!

To further ongoing IR learning, all congress delegates benefit from full access for a whole year.

www.esir.org

Cardiovascular and Interventional Radiological Society of Europe

Percutaneous treatment of spinal metastases

Frederic Deschamps (EBIR)

The definition of the end-point(s) is the very first step of the management of spinal metastases in cancer patients, and must be discussed by a multidisciplinary board. The end-points can be both pain palliation and/or prevention of complications related to the bone metastases (Fig. 1).

For pain palliation, the main mechanism of the pain must be considered in order to choose the most appropriate first-line treatment:

- 1) pain related to a fracture requires stabilisation of the fracture, and
- 2) pain related to the tumour volume or to the inflammatory process requires tumour-cell destruction.

For prevention of complications in asymptomatic patients, the risk related to the bone metastasis (pathological fracture, tumour growth) must be balanced with the risk of the procedure itself as well as with oncological considerations, namely the life expectancy.

Thermal-ablation and percutaneous stabilisation techniques can be used as minimally invasive alternatives to radiotherapy or surgery, respectively.

Thermal-ablation techniques

The principle underlying thermal-ablation techniques (radiofrequency ablation, microwave ablation or cryotherapy) is to destroy the bone tumour cells with heat, which is particularly indicated for palliation to pain related to an inflammatory process (release of chemical mediators by the tumour cells) or related to the tumour volume (increased pressure within the bone, stretching of periosteum, compression of soft tissues). It is therefore an alternative to radiotherapy for palliation of bone metastases, either as

first-line treatment or after the failure of radiotherapy.

Many studies have shown that thermal-ablation techniques can significantly and sustainably reduce pain related to bone metastasis [1-3]. One prospective multicentre trial [1] has reported that radiofrequency ablation achieved a 3-point reduction in pain severity in 40% of patients after 1 week, in 55% after 3 weeks, and in 84% at some time after treatment in 43 patients with lytic bone tumours, causing an average pain scoring of 7.9 points on a pain-assessment scale ranging from 1 to 10 points.

In patients with long life expectancy, local destruction of bone metastases can be performed with a curative intent in order to prevent local progression or to avoid a new line of systemic therapy (Fig. 2). Stereotactic body radiotherapy (SBRT) and thermal-ablation techniques are both effective options for this purpose. For thermal-ablation techniques, best results in complete local treatment have been demonstrated for small metastases (less than 2 cm), without any cortical bone erosion or neurological structures in the vicinity [4]. For both thermal-ablation techniques and SBRT, percutaneous stabilisation techniques are absolutely required in association in order to prevent bone insufficiency fractures related to the treatment itself.

Percutaneous stabilisation techniques

For patients with bone metastases, pain can also be related to fractures. The vertebral fractures can be either bone-insufficiency fractures or pathological fractures. Typically, the pain worsens with activity and decreases with rest. Based on this pain mechanism, stabilisation of the fracture is the key for palliation. Surgery is probably the most effective method for this purpose, but is


usually too invasive in many metastatic patients. Percutaneous stabilisation techniques (vertebroplasty, kyphoplasty, vertebral implant) are minimally invasive procedures that are performed under fluoroscopic or CT-guidance and involve minimal skin incisions. They are performed either with a palliative intent when fracture has already occurred, or with a prophylactic intent for consolidation of impending pathological fractures. They should not be considered as cancer treatment [5] but can be performed in association with radiotherapy or thermal-ablation techniques if destruction of the tumour is required.

Vertebroplasty consists of the injection of polymethyl-methacrylate within osteolytic metastases. For palliation, its benefit has been proven in many studies, which demonstrated pain reduction in 80 to 97% of cases [6, 7]. This benefit is obtained irrespective of the bone site treated [8]. However, vertebral and acetabular metastases (necessitating vertebroplasty and acetabuloplasty, respectively) are the most common and appropriate indications. Kyphoplasty (cavity created by balloon dilatation within the vertebral body) and vertebral implant procedures can be performed in association with vertebroplasty for better filling of the vertebral body and better mechanical consolidation.

Don't miss it!

State-of-the-art spinal tumour interventions
Special Session

Tuesday, September 29, 10:00-11:00
Room 3.A



Frederic Deschamps
(EBIR)
Gustave Roussy Institute
Villejuif, France

Dr. Frederic Deschamps is an interventional radiologist at the Gustave Roussy Institute. Dr. Deschamps is actively involved in various training efforts, including in biopsy techniques. He has delivered lectures at many CIRSE events, including CIRSE 2009, CIRSE 2011, ECIO 2014 and ECIO 2015, addressing topics such as RFA, nephrostomy, as well as percutaneous osteosynthesis and osteoplasty. He has particular expertise in liver neoplasms.

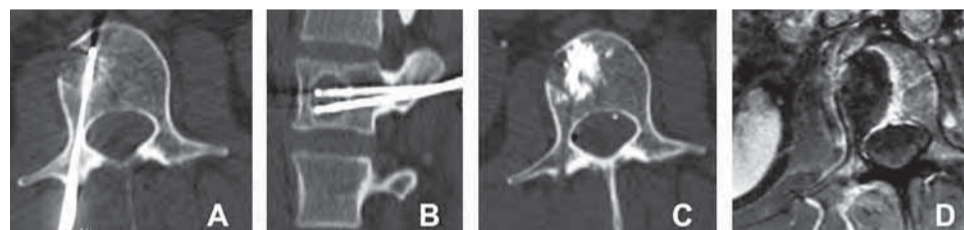


Fig. 2: Preventive destruction (images A and B: 2 probes of cryotherapy) and prophylactic consolidation (image C: vertebroplasty) in an oligometastatic female suffering from a single bone metastasis (L1) from breast cancer (long life expectancy). Image D: MR at 3 months.

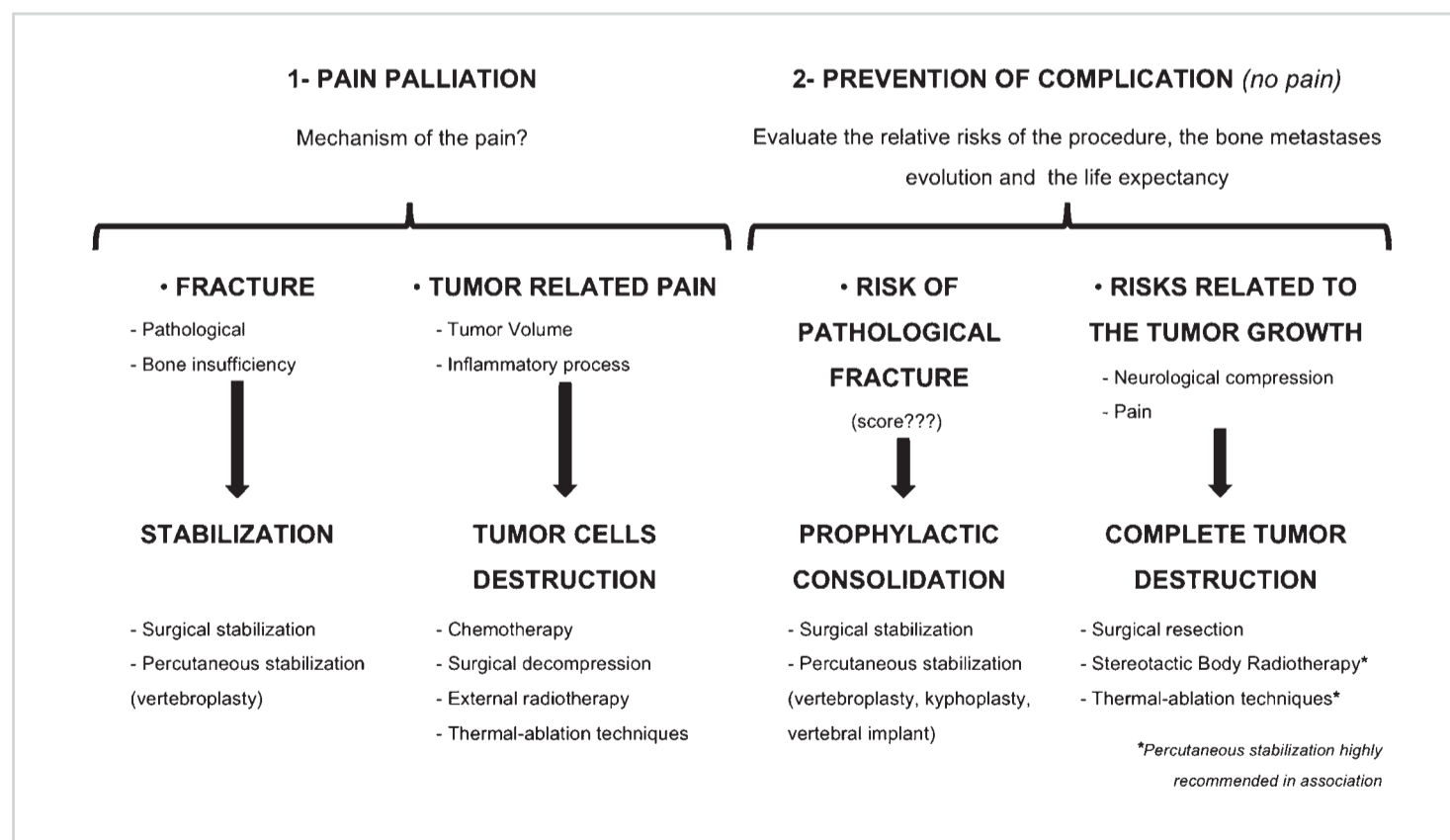


Fig. 1: Treatment options in the management of spinal metastases.

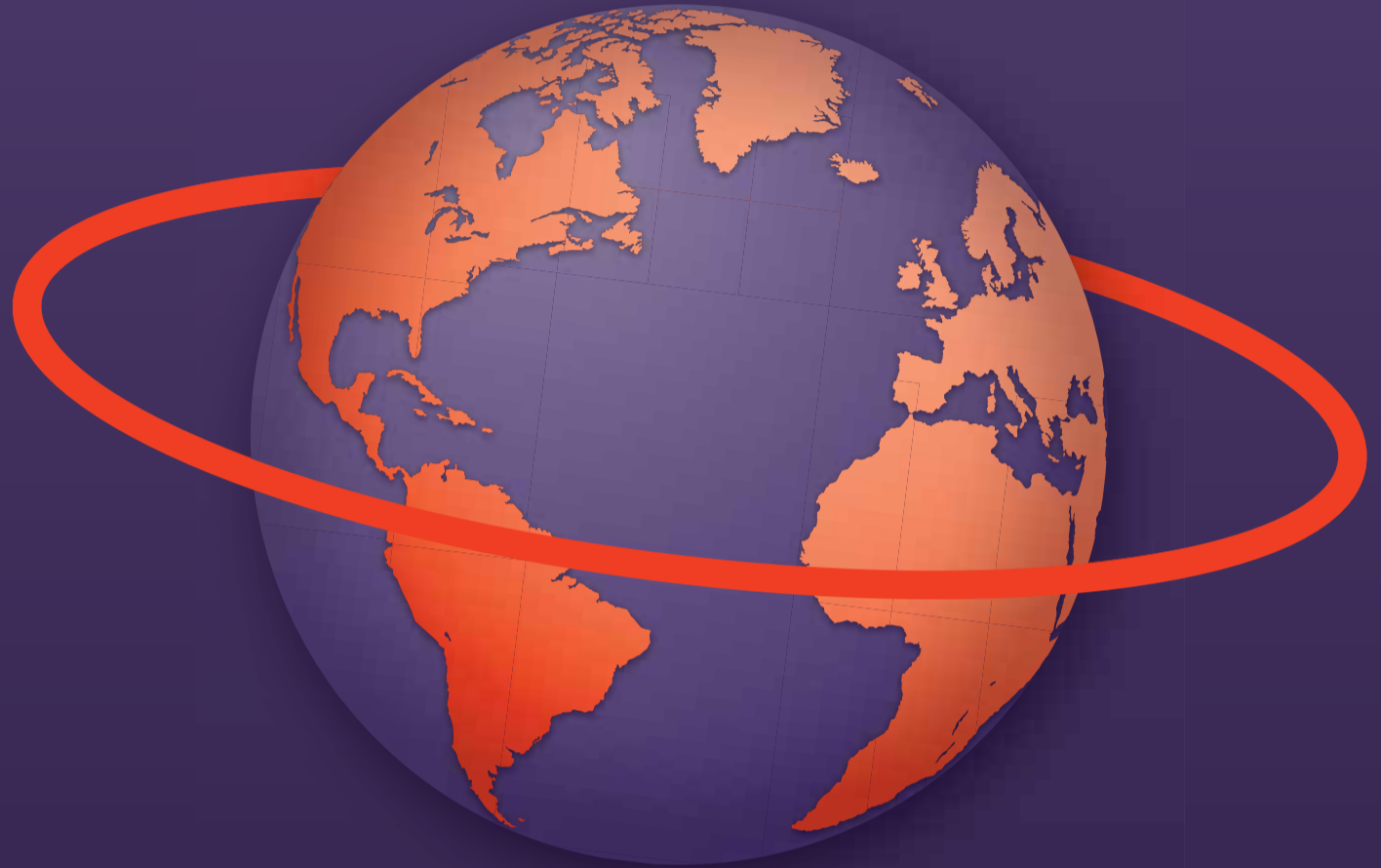References:

1. Goetz MP, Callstrom MR, Charboneau JW et al. Percutaneous image-guided radiofrequency ablation of painful metastases involving bone: a multicenter study. *J Clin Oncol* 2004; 22: 300-306
2. Kashima M, Yamakado K, Takaki H et al. Radiofrequency ablation for the treatment of bone metastases from hepatocellular carcinoma. *AJR Am J Roentgenol* 2010; 194: 536-541
3. Thanos L, Mylona S, Galani P et al. Radiofrequency ablation of osseous metastases for the palliation of pain. *Skeletal Radiol* 2008; 37: 189-194
4. Deschamps F, Farouil G, Ternes N et al. Thermal ablation techniques: a curative treatment of bone metastases in selected patients? *Eur Radiol* 2014; 24: 1971-1980
5. Munk PL, Murphy KJ, Gangi A, Liu DM. Fire and ice: percutaneous ablative therapies and cement injection in management of metastatic disease of the spine. *Semin Musculoskelet Radiol* 2011; 15: 125-134
6. Alvarez L, Perez-Higueras A, Quinones D et al. Vertebroplasty in the treatment of vertebral tumors: postprocedural outcome and quality of life. *Eur Spine J* 2003; 12: 356-360
7. Botton E, Edeline J, Rolland Y et al. Cementoplasty for painful bone metastases: a series of 42 cases. *Med Oncol* 2012; 29: 1378-1383
8. Anselmetti GC. Osteoplasty: Percutaneous Bone Cement Injection beyond the Spine. *Semin Intervent Radiol* 2010; 27: 199-208

CardioVascular and Interventional Radiology

The official journal of the Cardiovascular and Interventional Radiological Society of Europe

CVIR



**Send your manuscript around the world
by submitting it to CVIR – the international
platform for Interventional Radiology!**

- **Official journal of 19 national and regional societies**
- **Prominent Editors from 12 countries**
- **Editorial Board Members from over 24 countries**
- **Contributions from over 40 countries**
- **Truly international readership**

Today's Featured Papers

will be presented in the Free Paper sessions, taking place from 16:15-17:15 and from 17:30-18:30

16:15 – 17:15

FP 3005 Vascular: aorta Room 5.A

Long-term follow-up results of endovascular repair in the management of arterial stenosis caused by Takayasu arteritis
A. Gülcü, N.S. Gezer, S. Akar, N. Akkoç, F. Önen, A.Y. Göktaş; Izmir/TR

FP 3006 Liver TACE: experimental/ new frontier Room 5.B

Does DEB-TACE enhance the local effect of IRE? Imaging and histopathological evaluation in a porcine model
P. Isfort¹, P. Rauen¹, H.-S. Na¹, N. Ito², C. Wilkmann¹, C.K. Kuhl¹, P. Bruners¹;
¹Aachen/DE, ²Tokyo/JP

FP 3007 IVC filters Room 3.A

The impact of a prospectively maintained IR database on IVC filter retrieval rates
J.G. McGarry, K.A. Pennycooke, E. Ryan, P. Tharanatnam, S. Awaiahyan, M.F. Given, F. McGrath, A. Keeling, M.J. Lee; Dublin/IE

FP 3008 Lung ablation Room 1.15

Radiofrequency ablation versus surgery for the treatment of lung metastases: a comparative study
L. Tselikas¹, S. Yevich¹, T. de Baère¹, A. Auperin¹, O. Mercier², A. Hakimé¹, C. Teriitehau¹, E. FadeP¹, F. Deschamps¹;
¹Villejuif/FR, ²Plessis Robinson/FR

17:30 – 18:30

FP 3104 Venous intervention Room 5.A

Five-year outcome after catheter-directed thrombolysis for upper femoral and/or iliac vein thrombosis: results of a randomized controlled trial (the CaVenT study)
Y. Haig¹, T.R. Ender¹, O. Grøtta¹, P.M. Sandset¹, C.-E. Slagsvold¹, G. Sandbæk¹, G. Hafsahl¹, L.O. Holmen², N.-E. Kløw¹;
¹Oslo/NO, ²Fredrikstad/NO

FP 3105 IR in liver transplant Room 5.B

Identification of cofactors influencing hypertrophy of the future liver remnant after portal vein embolization: the effect of newly developing portal collaterals on embolized liver volume
M. Zeile, G.A. Stavrou, A. Bakal, J.E. Volkmer, P. Dautel, J. Hoeltje, A. Stang, K.J. Oldhafer, R. Bruening; Hamburg/DE

FP 3106 Kidney and ureter Room 3.A

Remote ischemic preconditioning to reduce contrast-induced nephropathy: a randomized controlled trial
T. Sterenborg¹, T. Menting¹, Y. de Waal¹, R. Donders¹, K. Wever¹, L. Suzan², D. van der Vliet¹, J. Wetzels¹, L.J. Schultze Kool¹, M. Warlé¹;
¹Nijmegen/NL, ²Doetinchem/NL

FP 3107 Portal vein (TIPS) Room 3.B

Single-centre experience of extending indications for percutaneous intra-portal islet auto-transplantation (PIPIAT) after pancreatic surgery to prevent type 1 diabetes (T1D): feasibility, technical aspects, complications, and clinical outcome
C. Sallemi, M. Venturini, L. Piemonti, G. Balzano, P. Maffi, A. Del Maschio, F. De Cobelli; Milan/IT

FP 3108 Miscellaneous Room 1.15

Severe gastrointestinal bleeding: a national confidential enquiry into the quality of care in patients requiring blood transfusion of 4 or more units
S.J. McPherson, N. Smith, M. Sinclair; London/UK

ESIR 2015 Course

Expert Course

The Future of Image-Guided Tumour Ablation – Targeting Techniques and High-End Clinical Strategies

Innsbruck (AT), December 11-12, 2015

This course brings together seasoned interventional radiologists to scrutinise the latest image-guidance systems and ablation methods.

Featuring a live case, product overviews and workshops examining individual imaging systems and discussing ablation devices, as well as forward-looking round-table discussions focusing on improving outcomes, the course promises to appeal to experienced practitioners dedicated to both shaping and further developing the future of interventional oncology.

Early Bird Fee available until October 16!

www.cirse.org/esir2015

CIRSE foundation





CIRT enrolls its 100th patient!

CIRSE is pleased to announce that its pivotal registry on radioembolisation with SIR-Spheres microspheres, the CIRSE Registry for SIR-Spheres Therapy (CIRT) has enrolled its 100th patient!

Just nine months after the launch of the registry in January 2015, CIRT is the largest observational study on the real-life application of SIR-Spheres in Europe, with hospitals enrolled from eight different countries, painting a diverse picture of the clinical use of SIR-Spheres microspheres in Europe.

CIRSE Registry for SIR-Spheres Therapy

For more information on CIRT, please visit www.cirse.org/cirt or contact Niels de Jong at dejong@cirse.org.

Cardiovascular and Interventional Radiological Society of Europe



ICCIR 2016

**International Conference
on Complications in
Interventional Radiology**



**June 9-11
Poertschach | Austria**

www.iccir.eu

CIRSE foundation

Save the Date!

As always, ICCIR 2016 will offer a discreet forum for doctors with diverse experience levels to explore the difficult but necessary subject of procedural complications.

Open Discussion

This unique congress allows participants to openly discuss cases that did not go as planned, and gives young doctors the opportunity to interact directly with colleagues who experienced such situations. The event attracts physicians who are strongly committed to keep perfecting their work. As a result, discussions are exceptionally frank, engaging and informative.

Unique Format

The event's discreet and professional environment is vital. The faculty is carefully selected and overall participation is limited. Hand-picked case reports constitute another essential element. This unusual approach has been tremendously popular, and ICCIR has quickly established itself as the main complications meeting in Europe. Don't miss your chance to take part in this exceptional event – mark your calendars now!

For more information, please visit: www.iccir.eu

Treatment and outcome: acute upper GI bleeding

Pierre Bize (EBIR)

Upper gastro-intestinal (GI) bleeding is defined as acute bleeding from a source located above Treitz's angle. A distinction should be made between chronic and acute upper GI bleeding as their consequences and management are quite different. Fifty to 60% of acute upper GI bleeding is related to ulcers. Other causes of upper GI bleeding include tumours, Mallory-Weiss syndrome and oeso-gastric varices due to portal hypertension. A distinction has to be made between cases where the bleeding is arterial in origin and cases where the bleeding is venous in origin, as their management will be totally different.

In the setting of acute GI bleeding there is usually no room for diagnostic imaging such as contrast-enhanced CT. Diagnostic imaging is reserved for the investigation of chronic GI bleeding. Acute upper GI bleeding must first be assessed via endoscopy after appropriate fluid resuscitation. Endoscopy allows for the identification of the bleeding source in most cases, and therapeutic haemostasis can be performed in the same session [1]. In case of arterial bleeding, injection of epinephrine and application of haemostatic clips are usually performed. The role of endoscopy in case of bleeding from a tumoural origin is often limited to diagnosis, as there are few efficient ways to control bleeding from these kinds of lesions endoscopically. In case of variceal bleeding, endoscopic band ligation (EBL) is the treatment of choice. Injection of sclerosants (aethoxysclerol) or cyanoacrylate can be an option in some cases. Gastric varices represent a challenging subset of variceal bleeding, with endoscopic treatment more difficult and fewer data available in the literature.

Interventional radiology plays an important role in case of a failure to control bleeding endoscopically. In case of arterial bleeding, transcatheter arterial embolisation (TAE) is the treatment of choice. Before engaging in this procedure, the interventional radiologist (IR) should get important information from the endoscopist, such as the nature and location of the bleeding source. Haemostatic clips placed in the vicinity of the bleeding artery can

provide important help to the IR seeking the culprit vessel. Whenever possible, clips should be placed onto or near the bleeding vessel as radiologic tags, even if they are deemed useless. After gaining access to the arterial system at the level of the common femoral artery (CFA), a selective digitally subtracted angiogram (DSA) of both the celiac axis (CA) and superior mesenteric artery (SMA) should be obtained. In most cases of arterial bleeding, the culprit vessel can be identified by the presence of vascular anomalies such as irregular vessel walls, pseudo-aneurysm, contrast blush or active extravasation. Provocative angiography or pharmaco-angiography, where vasodilative or thrombolytic drugs are administered intra-arterially to provoke bleeding, is not recommended.

In the vast majority of cases, the gastroduodenal artery (GDA) or one of its branches is responsible for the bleeding. Some authors even advocate systemic embolisation of the GDA when performing TAE for acute upper GI bleeding if there is no evidence of vascular anomaly [2]. A microcatheter should be used to reach the bleeding vessel, then coils should be used as the embolic material of choice. Because of the redundant vascular supply and numerous arterial anastomoses in the supramesocolic abdominal compartment, care should be taken to embolise the bleeding vessel on both sides of the vascular lesion to avoid re-bleeding (i.e. front door & back door technique). Particles can be used in case of bleeding from tumoural origin, but should never be used in any other setting as they will induce ischaemia, necrosis and, ultimately, perforation. Glue should only be used in severely bleeding, unstable patients, and carries higher risks of complications, such as wall necrosis and perforation. Nowadays, there is no room for intra-arterial vasopressin infusion.

Venous bleeding from portal vein hypertension (PVH) is a totally different story: patients with PVH will develop venous porto-systemic shunts in form of oesophageal or gastric varices. These fragile vessels are prone to bleeding

either from mechanical stress of just from PVH itself. As for bleeding from arterial sources, endoscopy should be performed first, as it allows diagnosis and treatment in most cases. When endoscopy fails to control bleeding, emergency placement of a transjugular intrahepatic porto-systemic shunt (TIPSS) should be considered. TIPSS is an artificially-created conduit between the portal venous circulation and one hepatic vein. Briefly, the right hepatic vein is catheterised from a right jugular venous access, and from there, a special trocar is used to puncture the right branch of the portal vein. Once access to the portal vein is obtained, the intrahepatic tract is dilated with a balloon catheter and a covered stent is put in place between the portal and hepatic venous systems.

This procedure allows the immediate lowering of the portal vein pressure and, in most cases, control of the bleeding. This procedure has the advantage of addressing the cause of bleeding, which is PVH. However, this procedure carries the risk of precipitating encephalopathy or causing acute liver failure by diverting all the portal blood flow away from the liver. It is always better to make the decision to perform this procedure in light of the general health status of the patient and the presence of comorbidities such as cirrhosis or cardiac failure. Early TIPSS (i.e. TIPSS performed within 72 hours of the initial bleeding episode) has shown good results in terms of bleeding control, with lower morbidity than emergent TIPSS [3]. In case of bleeding from gastric varices, balloon-assisted retrograde transvenous obliteration (B-RTO) of the varices is an interesting alternative [4]. Briefly, B-RTO consists of the retrograde occlusion of a spleno-renal vein. Through a jugular or femoral access, a balloon catheter is used to occlude the spleno-renal shunt, and cyanoacrylate or a sclerosant agent is injected to occlude the varices. Additional coils can be used to prevent migration of the occluding agent. This technique carries the advantage of limiting the risks of consecutive encephalopathy and preserving hepatic function. However, it does not address the problem of PVH.

Don't miss it!

GI tract haemorrhage
Special Session

Tuesday, September 29, 11:30-12:30
Auditorium 6



Pierre Bize (EBIR)
University Hospital of Lausanne
Lausanne, Switzerland

Dr. Pierre Bize is a senior physician in the Department of Medical Imaging at CHUV. He received his medical degree from the University of Geneva in 1993, and trained in general surgery, cardiac surgery and neurosurgery before focusing on radiology and interventional radiology. As an interventional radiologist, he specialises in tumour ablation and embolisation techniques, including chemoembolisation, and has particular expertise in the management of VX2 animal model trials. Dr. Bize has authored 24 peer-reviewed articles and 6 book chapters. Dr. Bize would like to acknowledge the contributions of Dr. Michel H. Maillard and Prof. Alban Denys, both of Lausanne, Switzerland.

In summary, we strongly believe that endoscopists and IRs are playing on the same team when dealing with patients with a condition as challenging as upper GI bleeding. If endoscopists can be regarded as the equivalent of defensive linemen on a football team, interventional radiologists should be seen as their linebackers.

References:

1. Hwang JH, Fisher DA, Ben-Menachem T, et al. The role of endoscopy in the management of acute non-variceal upper GI bleeding. *Gastrointestinal endoscopy*. 2012;75(6):1132-8
2. Loffroy R, Favelier S, Pottecher P, et al. Transcatheter arterial embolization for acute nonvariceal upper gastrointestinal bleeding: Indications, techniques and outcomes. *Diagn Interv Imaging*. 2015;96(7-8):731-44
3. Garcia-Pagan JC, Caca K, Bureau C, et al. Early use of TIPSS in patients with cirrhosis and variceal bleeding. *N Engl J Med*. 2010;362(25):2370-9
4. Saad WE, Darcy MD. Transjugular Intrahepatic Portosystemic Shunt (TIPSS) versus Balloon-occluded Retrograde Transvenous Obliteration (B-RTO) for the Management of Gastric Varices. *Semin Intervent Radiol*. 2011;28(3):339-49

ESIR 2015 Course

Expert Course Effective Hepatocellular Carcinoma (HCC) Treatments – Advanced Local Therapies Lausanne (CH), November 13-14


Minimally invasive treatments of HCC are of ever-growing importance, and ESIR's decision to offer an educational course structured around the condition itself rather than a single therapy reflects the complex variety of IR options that are currently available.

This course will address the whole spectrum of radiological interventions, from ablation to TACE and radioembolisation, as well as patient triage and indications and classifications.

www.cirse.org/esir2015



CIRSE foundation



IR Drugs and Doses – crucial pharmacology details at your fingertips!

CIRSE's new app contains essential information on pharmacological agents used by interventional radiologists in everyday clinical practice.

The app:

- Covers over 60 commonly encountered agents
- Information is divided into eight main categories: cardiovascular, contrast, embolic/thrombotic agents, GI-hepatic-pancreatic, haematologic, infection control, oncology and pain management
- Entries outline the agent's pharmacological properties, indications and contraindications; its proper administration; and, where applicable, available reversal agents
- Available for iPhone, iPad and Android

Prepared by experienced CIRSE members, IR Drugs and Doses serves as a handy guide for medical practitioners, trainees and students alike – **COMING SOON!**



Available for iOS and Android

INNOVATION | EDUCATION | INTERVENTION



Branching out beyond Europe

Places now available for corresponding members!

Register for the EBIR examinations to be held in Europe in 2016:

VIENNA, March 2-3, 2016

BARCELONA, September 9-10, 2016

Colleagues from Australia and New Zealand can also register for the EBIR examination held in cooperation with IRSA:

QUEENSTOWN, August 1-2, 2016

CERTIFY YOUR EXPERTISE!



For more information, please visit www.cirse.org/ebir



Bridging the gap between research and practice – ECIO 2016

The annual ECIO meeting offers all physicians interested in image-guided oncological therapies an opportunity to learn about new developments and discuss best practice. Since the early days of image-guided biopsies and palliative stenting, the field has expanded to cover a staggering range of clinical options.

Next year's meeting, to be held Dublin, Ireland, will endeavour to cover a broad cross-section of these therapies, focusing on the most recent advances. Under the new chairperson, Prof. Thomas Helmberger, the Scientific Programme Committee has already devised an exciting and varied programme.

Colorectal liver metastases

A core theme will be metastatic colorectal liver cancer. More than one million new colorectal patients are seen each year worldwide: approximately 15% of these have liver metastases at diagnosis and around 60% develop these during follow-up. Recent interventional oncology data demonstrate some promising adjuvant therapies, as well as increased survival time and improved quality of life in unresectable patients. These treatments and their clinical application will be thoroughly examined in number of Clinical Focus Sessions and a Multidisciplinary Tumour Board.

A varied programme

Other topics to be discussed include staples such as imaging, HCC, lung cancers, new developments and the clinical management of patients. 2016 will also feature a dedicated immunotherapy session – an exciting field which deserves the attention of the oncology community. The conference will also address newer clinical territories such as neuroendocrine tumours and cholangiocarcinoma, as well as hosting a discussion on quality assurance in the IO field.

The full scientific programme is already available online – visit the ECIO website for more details (www.ecio.org/2016).

Join us in Dublin!

These exciting sessions will take place in the Convention Centre Dublin, the first carbon-neutral convention centre in the world, whose striking glass frontage and curved walls offer the perfect backdrop to a field as dynamic and forward-thinking as interventional oncology. We hope to see you there!

To browse the Scientific Programme, please visit www.ecio.org/2016 or scan the QR code:



ECIO 2016

European Conference
on Interventional Oncology

April 17-20
Dublin, Ireland

www.ecio.org

General Information

Congress Date
April 17-20, 2016

Venue

The Convention Centre Dublin
Spencer Dock
Dublin 1
Ireland

Contact

CIRSE Central Office
Neutorgasse 9, Vienna
Email: info@cirse.org

LEADERS IN ONCOLOGIC INTERVENTIONS

CIRSE

Cardiovascular and Interventional Radiological Society of Europe

IR Congress News is published as an additional source of information for all CIRSE 2015 participants. The articles and advertorials in this newspaper reflect the authors' opinion. CIRSE does not accept any responsibility regarding their content. If you have any questions about this publication, please contact us at madden@cirse.org.

Editors-in-Chief: P. Haage, C. Binkert
Managing Editor: Ciara Madden, CIRSE Office
Graphics/Artwork: LOOP. ENTERPRISES media / www.loop-enterprises.com



CONTROL TAKES A **NEW SHAPE**

AZUR[®] CX

Peripheral Coil System

Tuesday, September 29, 2015

Symposium

13:00 - 14:00

Chairman: Pr T. Helmberger (Munich, Germany)

**"From loco-regional therapies in mCRC to
recanalization"**

AUDITORIUM 6