

IR congress news

CIRSE 2022 – Barcelona
Tuesday, September 13, 2022

SAVE THE
DATE!

Copenhagen
SEPT
9-13

CIRSE 2023

www.cirse.org

As CIRSE 2022 draws to a close, we are already looking forward to our next annual meeting which will take us to the beautiful city of Copenhagen. Surrounded by water, the relatively small Danish capital offers beautiful seascapes around every corner. Combined with its architectural delights both old and new, its unrivalled culinary scene, and its state-of-the-art congress centre, Copenhagen leaves nothing to be desired as our next host city.

Make sure to save the date to join us Sept. 9-13, 2023 for another great annual meeting!

Paediatric IR: developing excellence in IR for our youngest patients

Alex Barnacle

It is truly an honour to be invited to deliver this year's Roesch lecture on paediatric interventional radiology and to see so much paediatric IR in the CIRSE 2022 programme, as well as in the ECIO and ET programmes earlier this year. For years, paediatric IR has been a hidden part of our specialty, assumed by most to be a niche element of IR practised by a very small number of people with an interest in what is generally considered to be a difficult and challenging area. At best, I suspect that many feel that paediatric IR is a noble pursuit but not for them, best left to those who relish the complexities of that world. At worst, I wonder whether there are some who feel that it must be a futile, exasperating, and limited career choice.

I aim to reassure you all that both these views of paediatric IR are wrong. The scientific work presented by PIRs throughout this meeting and others, and the data published in recent years, form a growing body of evidence that we are right at the frontier of what IR can achieve in children. This is evidenced, for example, by the evolution of the IR management of renovascular and aortic hypertension in children (Fig. 1), the large volume of IR data from vascular anomalies management that comes from paediatric cohorts, and innovations in paediatric airway imaging and intervention (Fig. 2). Many of the very latest advances in adult IR are applicable in children. Innovators in this highly specialised field are leading the way by developing protocols and publishing data which will enable these interventions to then

be widely applied by those who are willing to expand their practice to include children. Those interventional radiologists who relished the excitement of innovation in the very early days of adult IR should look to paediatric IR for those same opportunities now.

At the same time, paediatric IR should no longer be considered niche or for specialists only. As IRs, we spend our time championing minimally invasive interventions as the standard of care for so many diseases and pride ourselves in being strong IR advocates for our adult patients. There is, however, a yawning discrepancy between what IR

procedures are offered to an adult and what may be offered to a child. Too many paediatric surgeons, oncologists and paediatricians are entirely unaware of what we can achieve. Too many paediatric healthcare commissioners and policy writers remain oblivious to IR as a specialty. Instead, far too many children continue to undergo open biopsies, non-image guided vascular access, aggressive surgery, or palliation without the option of IR alternatives, even across modern day Europe. We need to reflect on what healthcare the children in our own cities are being offered and champion minimally invasive interventions for them. This could simply be committing to developing

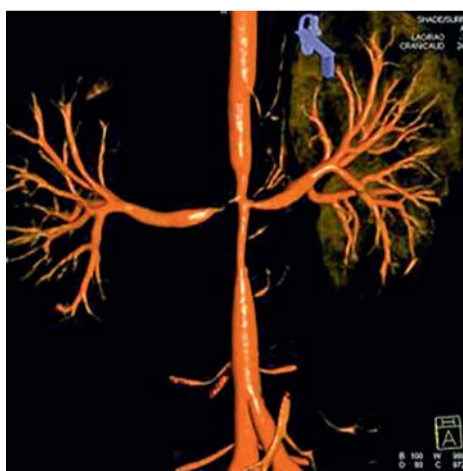

Figure 1: 3D abdominal aortic 3D rotational angiogram image in a 5-year-old male with mid aortic syndrome

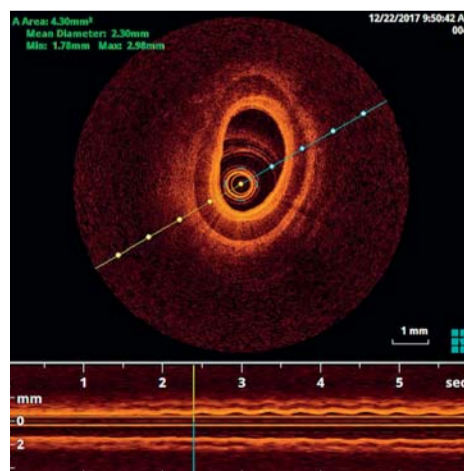


Figure 2: Optical coherence tomography (OCT) image of the distal trachea of a 5-week-old female with congenital long segment tracheal stenosis, showing complete tracheal cartilage rings

Don't miss it!

Josef Roesch Lecture

Tuesday, September 13, 14:30-15:00
Auditorium 1



Alex Barnacle
Great Ormond St Hospital
London/GB

Alex Barnacle is a paediatric interventional radiologist at Great Ormond Street Hospital in London, the largest paediatric IR unit in Europe and one of the busiest in the world. Her main interests are the diagnosis and management of vascular anomalies, paediatric renal stone disease, interventional oncology, and musculoskeletal intervention.

Dr. Barnacle has served two terms as President of the Society for Pediatric Interventional Radiology (SPIR) and has sat on the SPIR executive board for six years. She sits on the UK Royal College of Radiologists' IR committee as the representative for paediatric IR and is a member of the British Society of Interventional Radiology (BSIR) Communications and Women and Diversity Committees, as well as co-chair of their paediatric IR special interest group. In 2018, she was the BSIR/Royal College's Travelling Professor for IR and, in 2022, authored the national PIR policy guidance document for the UK.

Dr. Barnacle has worked within CIRSE as part of the CIRSE and ECIO Scientific Programme Committees, Membership Committee, and as Chair of the Social Media Subcommittee.



one small area of practice in our institution such as image-guided central venous catheters for children requiring lifelong access, image-guided tumour biopsies (Fig. 3), paediatric PCNLs (Fig. 4) or integration of paediatric protocols into our trauma policies.

We have seen a recent flourishing of interest in paediatric IR from medical students, trainees, and delegates at meetings such as this. I believe this has been prompted in part by the increasing presence of PIR on CIRSE's programmes, bringing paediatric IR into the mainstream. In turn, paediatric interventional radiologists get to exchange ideas with adult-focussed IRs from around the world.

As a subspecialty, we still have huge challenges to face, from the establishment of interventional oncology for children to

PIR inclusion in IR standards of practice and the 'normalisation' of paediatric IR within healthcare, so that children receive equitable care. But we should not need to reinvent the wheel. PIR can build on what IR has developed so far, learn from adult-focussed IR mentors and collaborate with IR centres, so that this is a shared journey. I am very grateful for the opportunity to highlight PIR at CIRSE 2022 and start that conversation.

References:

1. Barnacle AM, Cahill AM. Paediatric IR: the evidence for best practice is growing. *CVIR Endovasc* 2021;4:8
2. Hamed RK, Heran MKS, Patel M, Barnacle A, et al Challenges and opportunities for continued success and growth of Paediatric Interventional Radiology: A communique from the Society for Paediatric Interventional Radiology. *Am J Roentgenol* 2018;211:740-3

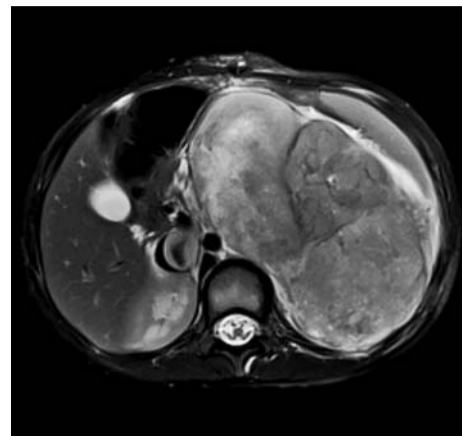


Figure 3: Axial MR image in a 5-year-old male with a left renal tumour and IVC tumour thrombus for biopsy and central venous access

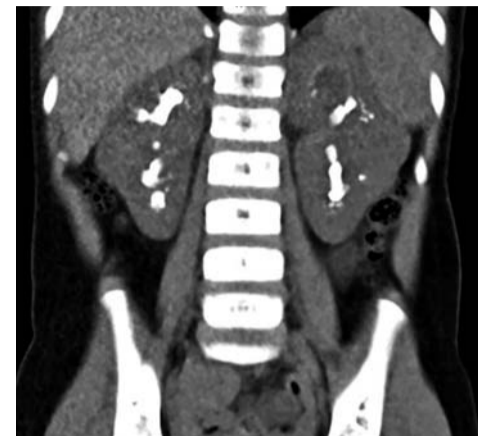

Figure 4: CT of a 3-year-old female with oxaluria and bilateral renal staghorn calculi, for PCNL

Don't miss it!

IR management of transplantation complications

Tuesday, September 13, 11:30-12:30
Room 117

Vascular transplantation complications

Marco Calandri



Marco Calandri
Città della Salute e della
Scienza Hospital
Torino/IT

Dr. Marco Calandri is an assistant professor and lecturer of radiology at the University of Torino, working as a diagnostic and interventional radiologist at "Città della Salute e della Scienza" Hospital in the same city. He obtained his medical degree cum laude in 2011 and completed his residency in 2017. During his residency, he visited, as an observer and as a visiting resident, the interventional radiology department of the Institut Gustave Roussy (Villejuif, Fr) and MD Anderson Cancer Center (Houston, US). He is an active member of the Italian Society of Radiology (SIRM), European Society of Radiology (ESR), and Cardiovascular and Interventional Radiological Society of Europe (CIRSE). He is the authorized representative for his center for the IASIOS accreditation. In his professional and scientific work, Dr. Calandri has been focussing on interventional oncology, with a specific emphasis on thermal ablation of colorectal liver metastases and liver transplantation. He has authored and co-authored more than 50 articles in peer-review journals, is co-author of book chapters, and has given over 60 invited lectures at national and international meetings.

Diagnostic radiology roots, multi-disease knowledge, multi-disciplinary approach

These key points can well describe the fundamentals of the future of interventional radiology. However, from another more fascinating perspective, they can identify the cornerstones of a specific setting, the role of interventional radiology in the management of vascular complications of liver transplantation. And this is why the IR approach to liver transplantation complications, with historical papers published a few years after the first liver transplant in 1963, can be considered the archetype of the IR contribution in many other scenarios, such as vascular or oncology.

Diagnostic radiology roots

As our interventional mentors taught us, everything starts from an adequate diagnostic work-up. Consistently, successful management of vascular complications starts from their early detection through regular doppler ultrasound and CT scans. Doppler ultrasound can be easily performed in the operating room, in the ICU, and then during follow-up in the radiology department. A precise analysis of the arterial flow can give information on arterial stenosis including peak velocity, resistive index and tardus parvus waveform.

Multiphase CT including arterial phase can precisely identify the site of the arterial stenosis and it is fundamental before any surgical, transarterial or percutaneous intervention. Furthermore, timing is a relevant factor both for the detection of stenosis and thrombosis, for the hepatic artery and portal and hepatic veins. Interventional radiologists, before moving to the angio suite, should be well aware of the precise setting in which they are asked to operate.

Multi-disease knowledge

A versatile knowledge of different vascular districts is of paramount importance for the correct management of liver transplant complications, being aware that codependent

modifications of arterial, portal, and hepatic vein flows can occur during follow-up. Furthermore, a correct approach to vascular complications should always include a deep knowledge of potential biliary complications. The interaction between arterial damage and biliary complications is well-known and relevant, since up to 80% of biliary complications are related to arterial stenosis or thrombosis.

Arterial flow stop to the transplanted organ due to severe stenosis or thrombosis requires varying treatments, depending on the timing of the onset of the complication. Early complications are more prone to re-surgery, whereas late-onset suggests a more cautious approach, including a watch and wait strategy and angioplasty or stenting, depending on the site and extension.

Portal vein stenosis is a very rare complication, slightly more common in split grafts, specifically pediatric ones. The increased incidence in pediatric split grafts is due to size mismatch between the donor's and the patient's portal vein. Percutaneous transluminal angioplasty is a valuable therapeutic option. However, restenosis is frequent, especially in children, due to elastic recoil and anatomical changes during growth. Stenting can be an option in these cases; the indication of bare metal stent placement should always be carefully evaluated due to the high risk of interference in case of retransplantation.

Inferior vena cava stenosis occurs in <1% of liver transplanted patients. The main causes of stenosis immediately after transplantation are size mismatch, twisting, dissection, or technical issues. Late stenosis, however, is most often due to perivascular fibrosis, but it may also be caused by compression or twisting of the graft.

Treatment of inferior vena cava stenosis will require repeated balloon angioplasty and ultimately stent placement, however, the risk of stent migration, malposition, or occlusion of the hepatic vein ostium should be always considered.

Multidisciplinary approach

As described above, the interventional radiology portfolio for the treatment of liver transplant complications today is diverse and enriched with new devices. Techniques have improved enormously in recent years, especially in the venous field.

However, the best therapeutic approach should always consider the high need for organ preservation and should never interfere with the possibility of retransplantation. Furthermore, in a real multidisciplinary setting, surgery and medical care should always be carefully evaluated as other valuable options.

In conclusion, an optimal diagnostic phase, a versatile knowledge of the different complications (arterial, venous, but also biliary), and the awareness of the many available treatments are the cornerstones for IR practice in the present and the future of liver transplantation.

References:

1. Interventional radiology in the management of the liver transplant patient. Thornburg B, Katariya N, Riaz A, Desai K, Hickey R, Lewandowski R, Salem R. *Liver Transpl*. 2017 Oct;23(10):1328-1341. doi: 10.1002/lt.24828.
2. IPerez-Saborido B, Pacheco-Sanchez D, Barrera-Rebollo A, Asensio-Diaz E, Pinto-Fuentes P, Sarmentero-Prieto JC, et al. Incidence, management, and results of vascular complications after liver transplantation. *Transplant Proc* 2011;43:749-750.
3. IPulitano C, Joseph D, Sandroussi C, Verran D, Strasser SJ, Shackel NA, et al. Hepatic artery stenosis after liver transplantation: is endovascular treatment always necessary? *Liver Transpl* 2015;21:162-168.
4. I Rostambeigi N, Hunter D, Duval S, Chinnakotla S, Goltzarian J. Stent placement versus angioplasty for hepatic artery stenosis after liver transplant: a meta-analysis of case series. *Eur Radiol* 2013;23:1323-1334.
5. IShibata T, Itoh K, Kubo T, Maetani Y, Shibata T, Togashi K, Tanaka K. Percutaneous transhepatic balloon dilation of portal venous stenosis in patients with living donor liver transplantation. *Radiology* 2005;235:1078-1083.

Bone tumour management: Pitfalls and complications to avoid

Georgia Tsoumakidou

Don't miss it!

Bone tumour management

Wednesday, September 14, 11:00-12:00

Room 115

Percutaneous interventional radiology treatments play an important role in the curative management of benign osseous tumours (i.e. osteoid osteoma, osteoblastoma, aneurysmal bone cyst) and oligometastatic bone disease. Furthermore, they can be used with a palliative intent in order to improve symptoms and decrease the risk of skeletal related events (i.e. pathologic fractures, compression of the spinal cord or nerve roots, life-threatening hypercalcemia) in patients with multiple bone metastases.

It is essential to define the therapeutic strategy, curative versus palliative, and choose the most adapted treatment modality considering the nature of the bony lesion, the patient's prognosis, quality of life, postoperative function and risk of post-treatment complications. Curative treatment of oligometastatic disease signifies that an ablative technique is used to achieve tumour destruction. In comparison, palliative treatment of an osteolytic lesion in weight-bearing bones necessitates some type of consolidation and cement injection in order to increase the bone's resistance to compressive stress. Ablative and consolidation techniques are associated whenever indicated.

IR procedures for the management of bone tumours have a favourable safety profile, with clinically significant complications being uncommon (2.3-5.5%) [1, 2]. Secondary fracture (1.8-5.5%) is one of the most common complications encountered after bone thermal ablation [1, 3, 4]. Lesions involving weight-bearing bones, the presence of cortical disruption, the extra-bone extension of the disease, the large tumour volume and prior radiotherapy are all predisposing factors for post-ablation insufficiency fractures [3]. According to the anatomic location of the lesion and the subjected forces (compression, tension, torsion or shear), consolidation with cement injection and/or osteosynthesis (screws, nails) should be considered to prevent post-ablation insufficiency fractures.

Although not common (<5%), neural thermal injury can arise when treating tumours in proximity to neural structures (nerves, spinal cord). Neural complications during spinal ablations occur between 1.7 and 16% [5, 6]. It is mandatory to be familiar with the cross-sectional anatomy in order to recognise the structures at risk. Treating spinal lesions can result in thermal damage of the spinal cord and spinal nerve roots. Sacral lesions are often in close distance to the sacral nerve roots and sacral plexus. The posterior acetabulum and ischial spine ablations can be complicated with sciatic nerve injury. Upper thoracic and shoulder treatments can put the brachial plexus at risk. Prolonged exposure of a neural structure to extreme temperatures (>40°C and <10°C) results in local neurolysis and interruption of electrical conduction, which can be temporary, usually resolving between 6-18 months, or permanent. Therefore, it is crucial to consistently re-examine the anatomy in order to recognise the neural structures in proximity and thus, to be able to take all necessary precautions in order to actively and passively protect the neural structures at risk. More challenging locations may require some type of thermal- (thermocouples) and/or neuro-monitoring (electrostimulation of motor nerves, somatosensory and motor evoked potentials).

Other infrequently observed complications after bone thermal ablation include: site infection, hematoma (0.5%), skin burns (2.8%) and skin frost-bite lesions, tumour seeding, avascular necrosis, arthropathy (0.9%) and pneumothorax (0.9%) [3]. Skin burns can be produced when the bone trocar is not sufficiently retrieved; thus, the active point of the electrode is not completely exposed. Skin burns can also be produced when treating superficial lesions in proximity to the epidermis [7]. In the second case scenario, sufficient hydro dissection of the subcutaneous fat can provide the necessary safety distance between the ablation zone and the epidermis. Cryoshock has not been reported yet after bone cryoablation.

Accessing blastic bone lesions can be challenging. In order to avoid device breakage, drills should be considered for bone penetration. Furthermore, operators need to dispose of grasping implements and be familiar with the different described practical tips [8] in order to be able to retrieve any retained fragments.

Cement leakage is not a rare phenomenon during cementoplasty, but in the majority of patients has no clinical manifestations. High quality real-time imaging (fluoroscopy) and careful monitoring of the spinal canal and epidural-paravertebral veins allow on-time recognition of any cement leakage.

To conclude, percutaneous bone tumour treatments are both safe and effective in the hands of experts. Several conditions need to be taken in consideration in order to early identify pitfalls and diminish complications.

References:

1. Autrusseau PA, et al. Safety and efficacy of percutaneous Cryoablation of extraspinal thyroid cancer bone metastases with curative intent: Single-center experience with a median follow-up of more than 5 years. *JVIR* 2022 <https://doi.org/10.1016/j.jvir.2022.03.016>
2. Cazzato RL, et al. Percutaneous microwave ablation of bone tumours: a systematic review. *Eur Radiol* 2021; 31(5):3530-3541
3. Cazzato RL, et al. Complications following percutaneous image-guided radiofrequency ablation of bone tumors: a 10-year dual-center experience. *Radiology* 2020;296(1):227-235
4. Auloge P, et al. Complications of percutaneous bone tumor cryoablation: a 10-year experience. *Radiology* 2019; 291(2):521-528
5. Tsoumakidou G, et al. Percutaneous image-guided laser photocoagulation of spinal osteoid osteoma: A single-institution series. *Radiology* 2016;278(3):936-43
6. Nakatsuka A, et al. Percutaneous radiofrequency ablation of painful spinal tumors adjacent to the spinal cord with real-time monitoring of spinal canal temperature: a prospective study. *Cardiovasc Intervent Radiol* 2009;32:70-5.
7. Parisot L, et al. CT-guided microwave ablation of osteoid osteoma: Long-term outcome in 28 patients. *Diagn Interv Imaging* 2022;S2211-5684(22)00073-0
8. Cazzato RL, et al. Percutaneous management of accidentally retained foreign bodies during image-guided non-vascular procedures: Novel technique using a large-bore biopsy system. *Cardiovasc Intervent Radiol* 2016;39:1050-1056



Georgia Tsoumakidou
University Hospital of
Lausanne, Lausanne/CH

Dr. Georgia Tsoumakidou is a consultant interventional radiologist at the University Hospital of Lausanne, Switzerland. She received her medical degree from the University of Athens in 2003, a master's degree in interventional radiology in 2006 and completed her radiology residency in 2010. She then performed a two-year fellowship in the University Hospital of Strasbourg in France, where she subspecialised in image guided percutaneous procedures, with a special interest in musculoskeletal interventions and MR-guided procedures. The focus of her clinical practice is oncologic interventions, both vascular and percutaneous, with particular reference to liver locoregional therapies, pain management procedures and MSK interventions. Dr. Tsoumakidou is an active member of CIRSE and serves as a reviewer for *CVIR*, *European Radiology* and *Skeletal Radiology* journals. She has authored and co-authored more than 60 articles in peer-review journals and is a co-author of several book chapters. During the past years, she has been awarded the *Magna Cum Laude* and *Cum Laude* distinctions at *CIRSE*, *ECR* and *RSNA* congresses for ten *EPOS* presentations.

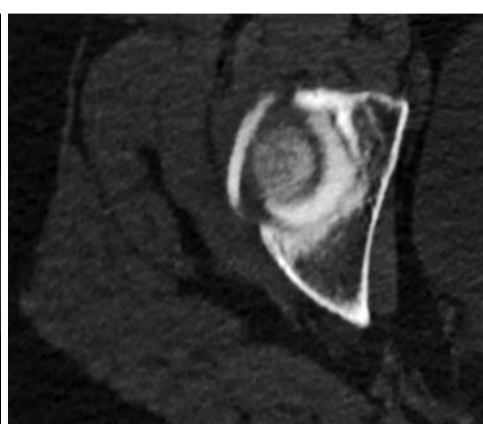
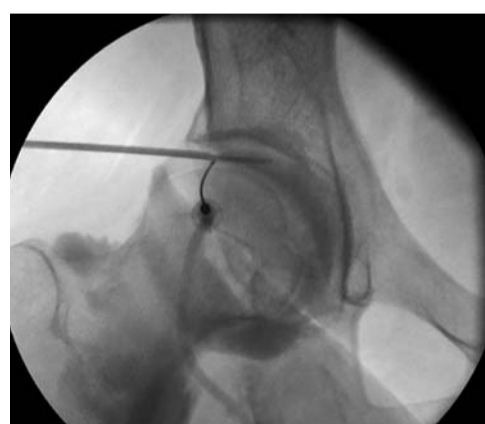

Figure 1A, 1B: Laser ablation of a juxta-cortical osteoid osteoma of the acetabulum. Hydro-dissection of the articular cavity was performed to protect the articular cartilage from thermal injury.

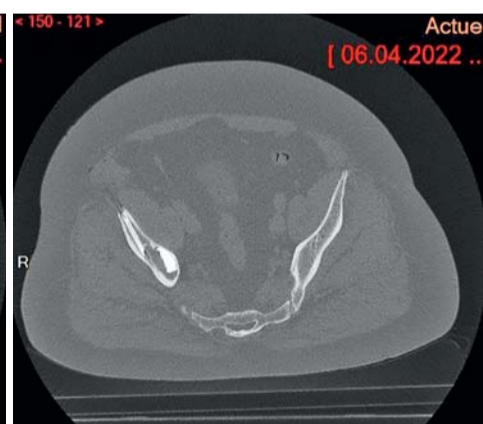
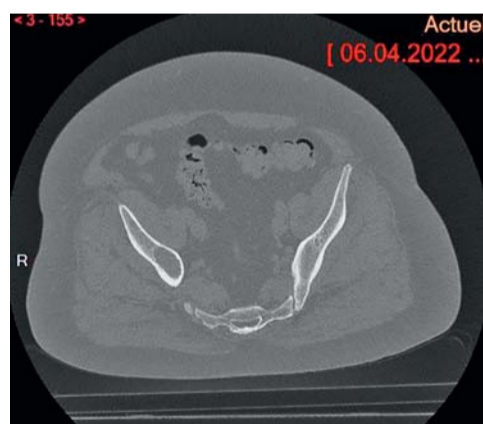
Figure 3A, 3B: Cryoablation and cementoplasty of a right iliac metastasis. Due to the hardness of the bone, the thickness of the soft tissues and the manipulations on the bone trocar, there was breakage of the coaxial bone needle during bone penetration. The needle fragment was left in place, as it was completely intraosseous.

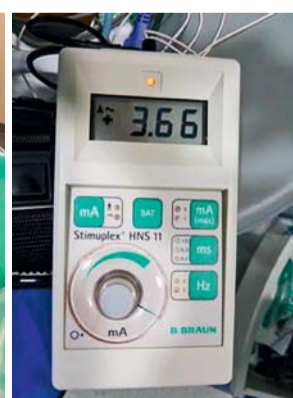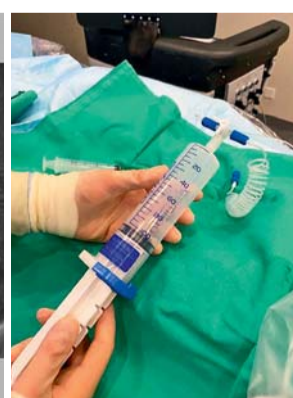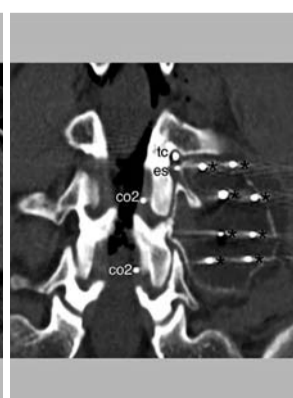
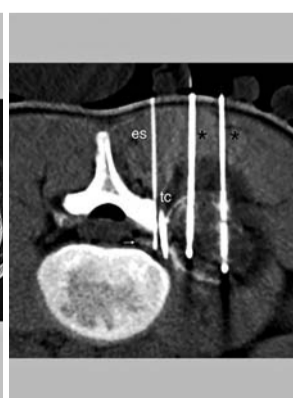
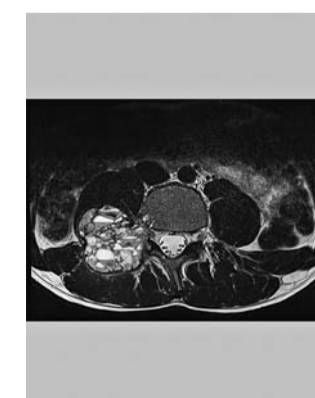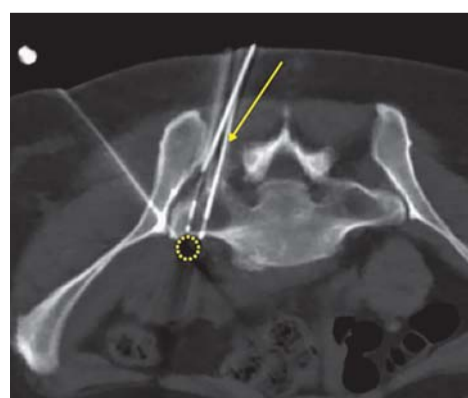


Figure 2: Curative cryoablation of a breast cancer metastasis on the sacrum in proximity to the sacral plexus. Thermal monitoring of the sacral plexus (thermocouple) and hydrodissection were used to avoid the neural thermal damage.

Figure 4A, 4B: L4 aneurysmal bone cyst treated with cryoablation. Figure 4C, 4D, 4E. Electrostimulation and CO2 dissection of the epidural space were necessary in order to avoid neural thermal injury.

Don't miss it!**Advanced technology in IO**

Tuesday, September 13, 08:30-09:30

Room 112

**Reto Bale**Medical University of
Innsbruck, Innsbruck/AT

Prof. Reto Bale has been the deputy director of the department of radiology and the division chief of interventional oncology and micro-invasive therapy at the University of Innsbruck since 2020. His main research areas include stereotactic thermal ablation (SRFA, SMWA, SIRE) 3D-navigation, and image fusion: CT- MR- PET- SPECT-ultrasound. He has collaborated in the development of numerous patents, including the VBH (Vogele- Bale- Hohner) Head holder, the Image-Guided Surgery System (Philips, EasyTaxis™), and the Targeting device (Medtronic, VERTEK™), among others. From 2014 to 2016, Prof. Bale headed the Austrian Society of Interventional Radiology (ÖGIR).

References:

- Bale R, Freund M, Bodner G, et al. Precise Computerassisted Liver Tumor Puncture for Biopsy and Thermal Ablation. *Radiology* 2002;225:242.
- Laimer G, Schullian P, Jaschke N, et al. Minimal ablative margin (MAM) assessment with image fusion: an independent predictor for local tumor progression in hepatocellular carcinoma after stereotactic radiofrequency ablation. *Eur Radiol* 2020;30:2463-72.
- Schullian P, Johnston E, Laimer G, et al. Thermal ablation of CT "invisible" liver tumors using MRI fusion: a case control study. *Int J Hyperthermia* 2020;37:564-72.
- Bale R, Schullian P, Eberle G, et al. Stereotactic Radiofrequency Ablation of Hepatocellular Carcinoma: a Histopathological Study in Explanted Livers. *Hepatology* 2019;70:840-50.
- Schullian P, Johnston EW, Putzer D, et al. Safety and efficacy of stereotactic radiofrequency ablation for very large (≥8cm) primary and metastatic liver tumors. *Sci Rep* 2020;10:1618.
- Schullian P, Putzer D, Eberle G, et al. Simultaneous Stereotactic Radiofrequency Ablation of Multiple (≥ 4) Liver Tumors: Feasibility, Safety, and Efficacy. *J Vasc Interv Radiol* 2020;31:943-52.

Fusion imaging, navigation, and planning

Reto Bale

Interventional oncology must become reliable and reproducible. Especially in tumours greater than 2-3 centimetres, complete in sano ablation from a single-probe position may not be possible despite the use of the latest MWA technology. In such cases, multiple overlapping ablation zones are required which can only be achieved by precise placement of multiple needles or by multiple needle repositionings. These tasks are difficult to achieve under conventional US-/CT-guidance. Technical solutions for 3D- planning, image guidance, and image fusion already exist.

The percutaneous stereotactic ablation workflow our team developed includes all these features, and it may be used in combination with any available ablation technology. Since our first stereotactic radiofrequency ablation (SRFA) in 2001 [1], followed by the first stereotactic microwave ablation (SMWA) in 2008, the first stereotactic irreversible electroporation (SIRE) in 2013, and the first stereotactic cryo ablation in 2014, we successfully treated > 4,000 primary and secondary liver tumours in > 1,000 patients with percutaneous stereotactic thermal ablation (mainly SRFA).

The stereotactic approach allows for precise three-dimensional planning and placement of multiple needles/probes in order to achieve overlapping ablation zones to cover large tumours.

Image fusion should be mandatory for every ablation procedure

Image fusion [2] is an integral part of the workflow and allows for immediate intraprocedural verification of the safety margin, which is an independent predictor of treatment success. Image fusion software

is used to superimpose the intraoperative contrast-enhanced control CT to the planning CT for verification of complete coverage of the tumour by the ablation zone. It enables the interventional radiologist to see the results of stereotactic thermal ablation before the patient even wakes up. This intraoperative verification is a key advantage as compared to radiation therapy, which requires waiting until long-term follow-up imaging has been completed.

Image fusion is integrated into our stereotactic neuronavigation system and has been used since our very first SRFA in 2001. However, if a stereotactic system is not available, one should at least use a stand-alone image fusion software during every conventional CT-guided percutaneous ablation.

Thermal ablation of CT 'invisible' liver tumours using MRI fusion

In a recent study [3], 60 patients with 199 lesions not visible in CT underwent SRFA using MRI-fusion and were compared to a matched control group without image fusion. In the fusion group, major complications occurred in 8.7%. The LR rate was 3.5% in HCCs and 4% in metastases. The LR rate of metastases in the control group was significantly higher, although differences in OS and DFS did not reach statistical significance.

Histopathological results after SRFA

In a recent study [4] published in *Hepatology*, we reported the effectiveness of SRFA for hepatocellular carcinoma in 97 patients for bridging to liver transplantation. A complete histopathological response was achieved in 183 of 188 nodules (97.3%). Despite the use of SRFA alone, 50 of 52 nodules >3 cm (96.2%) showed complete response in explant histopathology.

Short- and long-term outcomes after SRFA

The short- and long-term outcomes after SRFA are comparable to liver surgery, even in non-resectable patients, in patients with multiple lesions, and in patients with lesions up to >10 cm in diameter.

Due to the excellent results, stereotactic RFA has replaced surgical resection as the first-line treatment in Innsbruck in most liver tumour cases. Despite treatment of large lesions [5] and multiple lesions [6] simultaneously in one session, the complication rate after 2011 was 0.5% mortality and 6% major complications. More than half of these major complications could be treated in the same session by the interventional radiologist.

Since the implementation of SRFA including image fusion at our center in Innsbruck, the number of curative treatments in patients with primary and secondary liver tumours increased from 70 in 2001 to 280 in 2019 (+370%). The additional use of stereotaxy and image fusion enables the interventional radiologist to treat more patients more consistently, with curative intent, minimally invasively, and while sparing functional liver tissue.

Stereotactic thermal ablation is easy to learn, as the most difficult parts of the procedure (3D- planning) can be trained on virtual patient datasets. In conclusion, the additional efforts of 3D planning, stereotactic needle placement, and image fusion compared to conventional US- and CT- guided ablation approaches are justified by the excellent results that stereotactic thermal ablation yields.

Experience Barcelona History

Elizabeth Wenzel

CIRSE Communications Department

Alas, we cannot run hands-on device trainings around the clock – but you can spend your evening getting your hands on some of the more tangible aspects of Barcelona's long and multifaceted history.

What is Hercules doing here?

The origins of the city name are steeped in legend.

Some attribute the naming of the city to Hercules, who is said to have lost the ninth ship in his fleet during a storm in the area during his search for the Golden Fleece. After days of searching alongside his brother, Hermes, the ships' crew was found unharmed near Montjuïc. Enchanted with the area, they named it "Barca Nona" – the ninth ship.

Other say that the Carthaginian general, Hamilcar Barca, founded and named the city "Barcino" after his family sometime in the third century BCE.

Though both stories are now considered to be legends, the definitely real, historical Hamilcar Barca would probably be dismayed to know that he falls short of the mythical Hercules in the hearts and imaginations of Barcelona's

residents; statues and imagery of Hercules and Hermes can be found throughout the city. Impress your friends by telling this story every time you see them!

A Roman city lies beneath your feet

Though the city's most popular naming stories are probably apocryphal, the ancient Roman city was indeed once called "Barcino," the name was formalised at the end of the reign of Caesar Augustus somewhere around 14 AD. The city included a central forum, perpendicular main streets intersecting at the top of the Tàber hill, and was enclosed by defensive walls that are still visible in places.



If you've spent time in Europe, you've probably had your fill of cathedrals and vaguely room-shaped piles of rocks. If you'd prefer to walk where Roman residents walked, gaze upon mosaics, or generally marvel at how far laundry technology has come in the last 2,000 years, is still possible of visit ancient Barcino! The largest archaeological site in town remains beneath the Gothic Quarter and can be toured through the City History Museum of Barcelona.

Love Art Nouveau? You'll want to go to the hospital for that...

Barcelona contained six small hospitals at the end of the fourteenth century, all founded by religious individuals or orders, but largely funded by charitable donations from private citizens. Due to financial difficulties that any modern crowdfunder can empathise with, in 1401 the six hospitals were merged into one, the Hospital de la Santa Creu.

One of the oldest hospital complexes in Europe, the cloister-esque building set around a central courtyard was completed in 1450 and extended in subsequent centuries. By the nineteenth century, the hospital had established a reputation as one of the finest in Europe, but the building was beginning to crumble.

Luckily for the hospital, Barcelona was undergoing a great urban transformation during the last part of the 1800s. Also lucky for the hospital was the death of Pau Gil i Serra, a Catalan banker whose will left his estate to be dedicated to the building of a hospital in Barcelona, specifying that it should be an innovative combination of architecture and medicine dedicated to Saint Paul.

Thus, the Hospital de la Santa Creu i Sant Pau, one of the most prominent works of Catalan architect Lluís Domènech i Montaner, began construction in 1901.

This Art Nouveau masterpiece continued as a fully functional hospital until 2009, when a modern hospital opened next door. Today, it is a museum and culture centre which also includes an archive with documents on remarkable occurrences related to the hospital and the city. A few departments of the modern hospital (including the radiography department!) remain in the historical building complex.

The medieval Santa Creu hospital still stands as well, and today holds an art school and the National Library of Catalonia.

Robotic catheters and stereotactic guidance systems

Miltiadis Krokidis

Robotic systems were introduced in modern surgery more than two decades ago; they were established for clinical treatment in urology but rapidly expanded to other areas like general surgery, gynaecology, and orthopaedics. Nowadays, more than 6,000 Da Vinci robotic surgical systems (Intuitive Inc.) are available worldwide, and more than 1.3 million procedures are done robotically every year. This evolution offered a massive transition from traditional open and laparoscopic surgery to robotic surgery, benefiting patients, surgeons, and healthcare systems. However, in the field of endovascular therapies, robotic navigation has only recently been developed and is still not extensively integrated into everyday clinical practice.

The endovascular area where robotic technology appears to be used most frequently is electrophysiology procedures. Navigation in such procedures is performed via an external magnetic field. The concept was initially introduced in the early 1990s to perform diagnostic studies on neonates. A few years later, the first stereotaxis systems were developed using a 0.15T magnetic field. The first remote navigation system was the Niobe (Stereotaxis Inc), consisting of two permanent neodymium-iron-boron magnets. The magnets were placed on each side of the fluoroscopy table, and control was performed via an external computer [1]. The most novel evolution in this field is offered by the Genesis system (Stereotaxis Inc), which utilises smaller magnets that rotate along the centre of mass

and allows for very high responsiveness to physician control. The magnets are held on two flexible robotic arms, increasing the system's potential range of motion and offering wider angulation. The system is faster than its predecessors and has improved ergonomics. This specific system is designed for robotic electrophysiology, offering very satisfactory outcomes and becoming the new standard of treatment [2]. However, the use of magnetic field guidance for catheters may be applied in other endovascular fields in the near future, given that the concept offers catheter guidance "from the top", increasing precision and stability.

The control panel for such systems is located outside the room to optimise efficiency but also to offer the possibility of remote access. Telerobotics or "cockpit surgery" appears to be a growing trend within the spectrum of digitalised treatments, providing collaboration between centres for difficult cases.

A different technology was implemented in the construction of the Magellan, (Auris Surgical Robotics Inc.) which consists of a remotely steerable catheter system that provides manipulation by orthogonal pull-wires. The cockpit again is located outside the room, reducing the radiation exposure for the operator. Clinical outcomes of the system have been very positive in terms of reduction in target vessel cannulation time and catheter stability, particularly for complex procedures [3, 4].

A similar system is the CorPath GXR (Corindus Inc) which succeeded the previous CorPath 200 model. The system consists of two major components, a remote area of control (Figure 1c) and a "cassette" (Figure 1b) that is applied on a metallic arm (Figure 1a) fixed on the angiographic table. Vascular access is obtained, the required catheters are inserted in the "cassette" and then manipulation is performed from the remote position. Most of the evidence is produced for coronary intervention, but there is also some evidence from peripheral work, underlining the feasibility of the method, the precision of wire manipulation and the reduction of radiation for the operator [5, 6].

Furthermore, there is also a trend of transition from purely navigational robotic intervention towards "cognitive" robotic interventions, and more specifically, moving from the purely mechanical benefits of robot technology (precision, ability, safety, comfort) to outcome quality improvement (via increased intelligence, information, insight, and connectivity). This will be the expected transition towards "digital procedures" via image guidance and integration, automation, telerobotics and insight deduced from big data. Interventional radiology closely follows this field's continuous evolution and constantly integrates the available technology and evidence in everyday clinical practice.

Don't miss it!

Robotic and stereotactic approaches in IR
Wednesday, September 14, 08:30-09:30
Room 115



Miltiadis Krokidis
Areteion Hospital,
Athens/GR

Miltiadis Krokidis is a vascular and interventional radiologist at Areteion Hospital and an assistant professor at the School of Medicine of the National and Kapodistrian University of Athens, Greece. He has served in various positions in major European radiological societies and he is currently the IASIOS Committee Deputy Chairperson and the Advisor for Public Affairs for the CVIR Journal.



Figure 1: The CorPath GXR from Corindus Inc consists of a) a metallic arm that is fixed on the angiographic table, b) A "cassette" where the wires and the catheters are inserted, and c) a remote-control area of wire and catheter manipulation.

References:

1. Pappone C, Vicedomini G, Manguso F, et al: Robotic magnetic navigation for atrial fibrillation ablation, J Am Coll Cardiol 47:1390-1400, 2006.
2. Blandino A, Bianchi F, Sibona Masi A, Mazzanti A, D'Ascenzo F, Grossi S, Musumeci G. Outcomes of manual versus remote magnetic navigation for catheter ablation of ventricular tachycardia: a systematic review and updated meta-analysis. Pacing Clin Electrophysiol. 2021 Jun;44(6):1102-1114.
3. Riga CV, Bicknell CD, Rolls A et al. Robot-assisted fenestrated endovascular aneurysm repair (FEVAR) using the Magellan system. J Vasc Interv Radiol 2013; 24(2): 191-196.
4. Cochenec F, Koberter H, Gohel M et al. Feasibility and safety of renal and visceral target vessel cannulation using robotically steerable catheters during complex endovascular aortic procedures. J Endovasc Ther 2015; 22(2): 187-193.
5. Mahmud E, Dominguez A, Bahadorani J. First-in-human robotic percutaneous coronary intervention for unprotected left main stenosis. Catheter Cardiovasc Interv. 2016 Oct;88(4):565-570. doi: 10.1002/ccd.26550. Epub 2016 May 18.
6. Mahmud E, Schmid F, Kalmar P, Deuschmann H, Hafner F, Rief P, Cain C, Ang L, Brodmann M. Robotic Peripheral Vascular Intervention With Drug-Coated Balloons is Feasible and Reduces Operator Radiation Exposure: Results of the Robotic-Assisted Peripheral Intervention for Peripheral Artery Disease (RAPID) Study II. J Invasive Cardiol. 2020 Oct;32(10):380-384.

CIRSE academy

From curriculum to career

Whether you want to prepare for the EBIR exam, gain CME credits or simply test your knowledge on a certain IR topic, the CIRSE Academy is the right e-learning platform for you.

Designed to suit students and trainees as well as experienced IRs, the CIRSE Academy currently hosts more than 50 peer-reviewed courses.

Get a Digital All-Access Pass to explore all courses!

So far, the most popular courses in 2022 include:

- Management of acute arterial gastro-intestinal haemorrhage (2021)
- Hepatocellular carcinoma (2021)
- Fundamentals of PTA and stenting for peripheral arterial disease (2021)

Stay tuned for more CIRSE Academy content to be launched in the course of this year!

For a full list of available courses visit [cirse.org/education/academy/](https://www.cirse.org/education/academy/)



Don't forget to complete the event evaluation to provide feedback on the congress and claim your CME credits!



Don't miss it!

Hands-on device training: Varicose veins
 Tuesday, September 13, 09:45-11:15
 Room 132

Varicose veins – stop diagnosing (only) and start treating!

Felipe Veloso Gomes, Mark Regi



Felipe Veloso Gomes
 Hospital Cruz Vermelha
 Lisbon/PT

Dr. Felipe Veloso Gomes is a consultant interventional radiologist and endovenous specialist. He has worked in the IR Unit at Hospital Curry Cabral, Lisbon, Portugal, for the past eight years and developed a Varicose Vein Clinic at Hospital da Cruz Vermelha, also in Lisbon, in 2016. He organized the first Varicose Vein Workshop for IRs in Portugal in 2017.

Varicose veins are a manifestation of chronic venous disease (CVD), a highly prevalent condition, which causes significant impairment in quality of life of both women and men. The negative impact on a person's life arises from the physical signs, symptoms, and complications of the disease, but also from the negative aesthetics, leading to embarrassment.

The treatment of varicose veins has been performed by a variety of medical specialists, from vascular to general surgeons to dermatologists to angiologists, and, of course, interventional radiologists.

Recent developments in the endovascular treatment of saphenous vein reflux, which is the most common cause of varicose veins, have led to a change in its treatment: from surgery to minimally invasive treatments, and from the OR to the office. Interventional radiologists have arguably become the medical specialists with the most solid training to treat the spectrum of chronic venous disease, in particular superficial vein reflux.

The new treatment modalities include laser, radiofrequency ablation, superglue, steam, and microwave ablation. We can now use the totally non-invasive technique of HiFu to destroy veins. Most IR programmes include comprehensive training in the anatomy, diagnosis, and management of CVD, making IRs highly qualified to treat varicose veins. There are numerous examples throughout Europe of an increasing number of IRs dedicating themselves to the treatment of this pathology.

With a very high prevalence in the population and high demand for treatment, this is a very attractive area for any IR wishing to develop a private practice.

Considering the increasing demand for treatment and the growing involvement of interventional radiologists, it is essential to understand the breadth of knowledge around CVD and acquire basic skills for the treatment of varicose veins. We will showcase many of the newest technologies for the treatment of varicose veins in this workshop. It is a rapidly growing field for those who love new tech!

We have acquired ample experience in the field and will be happy to share it in this hands-on device training (HDT), aiming to provide an overview of duplex ultrasound of the lower limbs and the handling of a selection of devices and different treatment techniques available.

Join us and get ready to start treating!



Mark Regi
 Vein Centre
 Sheffield/GB

Dr. Mark Regi is a consultant interventional radiologist and endovenous specialist and education and training lead at Veincentre, UK. He performs over 500 venous procedures per year. He has worked as a consultant in Sheffield for the last 10 years leading the complex aneurysm and trauma IR services. He has run the varicose vein HDT in 2018 and 2019 prior to the COVID hiatus.

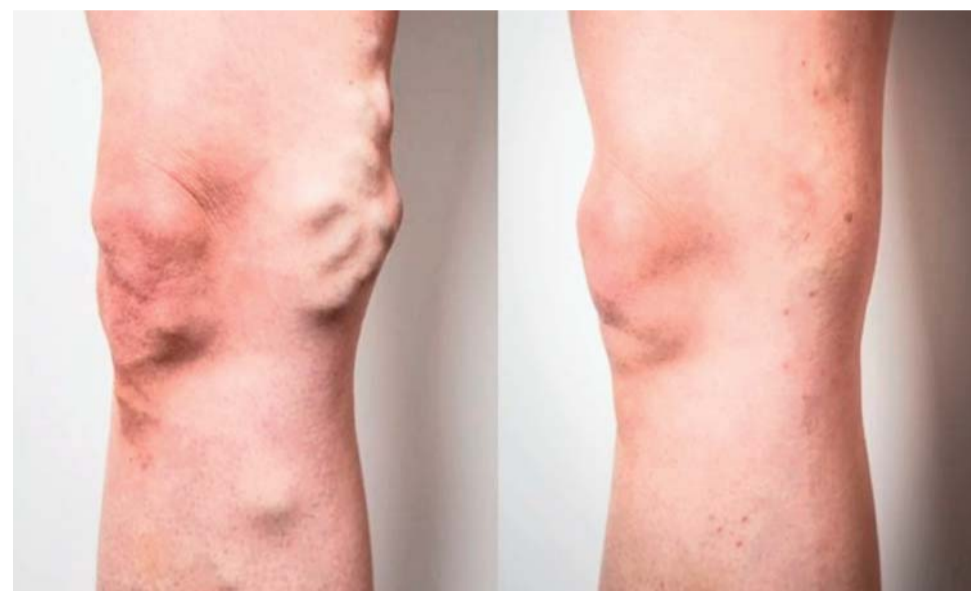

Figure 1: Varicose veins before and after treatment

References:

1. De Maeseneer M, Kakkos S, Aherne T, et al. Editor's Choice – Management of chronic venous disease: clinical practice guidelines of the European Society for Vascular Surgery (ESVS). *Eur J Vasc Endovasc Surg.* 2022; 63: 184-267. References

Interview with incoming Scientific Programme Planning Chairperson Prof. Adam Hatzidakis

Hatzidakis Adam
 CIRSE 2022
 SPC Deputy Chairperson

You have been coming to the CIRSE annual congress for many years. What have been your personal highlights?

Hatzidakis: For me, it was always a great pleasure to follow the Roesch and Gruentzig lectures given by great scientists and IR teachers. I'll never forget the experience of being there in person when Josef Roesch himself gave the first instalment of his eponymous lecture. This year, Dr. Alex Barnacle will give the Roesch lecture on Tuesday and Dr. Guiu will give the Gruentzig lecture on Sunday. I'm certainly looking forward to these!

On a light note, the quiz sessions are always such a great combination of stretching your brain while also having a good time with colleagues from the world over (I myself participated in two and organised another one).

Another highlight for me is watching innovative sessions like "Amazing Interventions," these are always fantastic because you can really see what

made our specialty what it is now: technical skills combined with fantasy!

In the past three years, you have served as SPC Deputy-Chairperson. What do you feel have been your greatest achievements in this time?

Hatzidakis: Certainly, the transition from live to virtual was a great achievement which was accomplished through the efforts of the CIRSE office and its staff. We cannot thank them enough for this! Making sure that IR education could continue uninterrupted has been the overarching challenge of the last two years, and it was essential that the SPC throw all efforts into guaranteeing that our online programmes remained at the high level our members expect and deserve.

What were the biggest challenges when creating a virtual congress for the 2020 and 2021 annual meetings?

Hatzidakis: The uncertainty of what to do each September and ensuring that the decisions were made early enough were big challenges for all, and then the technological problems and solutions that came after the decision to go remote were the next hurdle. I think the office and the Board took the right decisions and that the Society came out of this crisis improved and stronger than before, especially in the eyes of the other scientific societies and industry

partners, showing them how professional we can move and work. Also, a big compliment has to be given to all presenters who did a great job with this mixture of live and virtual presentations.

Which parts of the virtual congress will stay with us in the long run?

Hatzidakis: I think that throughout the COVID crisis we gained valuable tools which can be used in the future for online education and webinars year-round. The custom-built platform we created to host our online meetings is also very professional and can remain a great tool for those who want to watch annual congresses live and ask questions from home. It certainly brings a lot of value to everyone unable to be present to be able to continue watching remotely! Even for onsite attendees, being able to use the platform to catch up with anything they missed or review something from earlier in the day is a great advantage.

What are your plans for your tenure as the SPC Chairperson?

Hatzidakis: I am thinking about some different ideas for the programme and have a lot of exciting things to discuss with the new SPC Members. The outgoing committee did a great job the last three years and I am sure our incoming SPC will add value to the programme through new thoughts and suggestions. I

tried to choose eight IRs all from different European countries so that there will be a more representative synthesis in the committee. It is also my goal to incorporate more speakers and moderators from underrepresented countries in next year's programme. I am certain everybody will gain from this endeavour to build an intentionally international outlook into the very fabric of the programme.

When looking way ahead, where would you like to see the annual congress 10 years from now?

Hatzidakis: I am not a prophet, but I expect and hope that our joint presentations and co-operation with other clinical specialties will be enhanced. We've come a long way in that regard but should still strive to continue the upward trend! I also believe that the hands-on and simulation workshops are essential and we need to push to be sure that we have the newest applications of navigation and AI systems ready at hand for as many people as wish to learn, so that, with help from the industry, the educational goals of the congress can be achieved. Our congress is and will always be a great meeting of people, knowledge and technology. We will continue to expand, innovate and improve our activities; and certainly we will all, juniors and seniors, students and teachers, continue to treasure our experiences at CIRSE, the most amazing five days of the whole IR year!

Flared iliac limb vs. branched iliac stent graft: decision-making and durability outcomes

Said Abisi, Enming Yong

Introduction

The common iliac artery (CIA) is considered aneurysmal when ≥ 18 mm in men and ≥ 15 mm in women [1]. Current guidelines recommend treatment of isolated iliac aneurysms when it is more than 35mm in size [2].

Endovascular management options range from embolisation of the internal iliac artery (IIA) with stent graft coverage extending from the CIA to the EIA, to flared iliac limb or sandwich technique. More recent additions to the endovascular armamentarium include branched iliac stent grafts (IBD) with the first device successfully placed in 2001 [3]. These techniques help achieve the goal of excluding the CIA aneurysm sac by either sacrificing or maintaining hypogastric circulation [4]. Of note, there is currently no consensus on the optimal endovascular management of CIA aneurysms.

The role of preservation of the internal iliac artery

While traditional treatment of iliac artery aneurysms consisted of embolisation of the IIA and stent extension, there has been increasing focus on preserving the IIA where possible. Though IIA exclusion may be compensated by collateral pathways, up to one third of patients experience complications like buttock claudication (10-35%) and erectile dysfunction (3-16%) [5]. Severe ischemic complications like ischemic colitis, pelvic ischemia, and spinal cord ischemia are feared, albeit rare (<1%). Bilateral IIA occlusion is also associated with worse complications compared to unilateral occlusion [6].

As a result, the 2018 SVS and 2019 ESVS guidelines both recommend preservation of at least one IIA during open surgical repair or EVAR for aortoiliac aneurysms to provide sufficient pelvic organ perfusion and to reduce the risk of buttock claudication [2,7]. IIA embolisation is thus only recommended in the absence of an adequate iliac artery landing zone.

Key considerations

Considerations when deciding on treatment options include [8]

- Patient factors: age (less complex procedure for patients of advanced age), life expectancy, activity level (less likely to preserve IIA)
- Anatomical factors:
 1. Extent of aortic disease: if more extensive aortic coverage is anticipated in the future, the IIA should be preserved to mitigate the risk of spinal cord ischemia
 2. IIA tortuosity and diameter: tortuous IIA and small diameter (<6.5mm) IIAs associated with poor primary patency of IIA for IBDs
 3. Thrombus load
- Durability: Particularly for flared limbs which are affected by diameter of the iliac artery (<20mm) and length of the landing zone

Flared limbs

Ectatic and aneurysmal CIAs can be treated with flared iliac limbs, and this technique has been in use for numerous years. Iliac limbs that are up to 28mm are commercially available to land in iliac arteries measuring up to 25mm in diameter (Table 1). This technique has the advantage of proceduralist familiarity due to the lower complexity of the procedure, lower costs, lower amounts of contrast usage, and shorter operative time than IBDs [9]. An earlier study by Torsello in 2010 showed low (3%) rates of Type 1b endoleak with a mean follow-up of 56 months [10]. There were no aneurysm-related deaths, freedom from

secondary intervention was 91.6% at 5 years, and the mean diameter of the treated CIA aneurysms was 22.1mm. This study focused on CIA aneurysms less than 30mm and excluded patients with aneurysmal involvement of the IIA origin.

More recent studies show an association between flared limbs and late type 1b leak, with patients treated with iliac limbs >20 mm having a fivefold higher risk of late (mean 37 months) type 1b endoleak compared with patients treated with a distal iliac limb diameter <20 mm [11].

Given the above, flared limbs can be considered when iliac diameter is 20mm or less, or if the patient is of advanced age and a less complex procedure is required, while accepting reduced long-term durability. Expert consensus also suggests that the durability of the seal can be improved by aiming for at least 20mm of distal landing zone, and if it were less than that, IBD would be preferred [8].

Iliac branch devices

Endovascular grafts with iliac side branches are safe, effective and useful in sealing CIA aneurysms while maintaining IIA patency. They are associated with high technical success and minimal morbidity. Three devices are available commercially in Europe: Cook, Gore, and Jotec (Table 2).

Considerations when deciding on the use of IBDs include the need to position the IBD to facilitate IIA cannulation and anatomical factors like iliac artery tortuosity and thrombus load. There should be an adequate aortic to iliac bifurcation length (at least 50mm) and a sufficient diameter at the iliac bifurcation to ensure that the iliac side branch can open. There should also be a sufficient length and an appropriate diameter at the EIA and IIA landing zones.

A 2020 meta-analysis of 1,502 patients showed technical success of 97.5%. The 30-day patency of IBDs was estimated at 97.59% (95% CI, 96.49-98.54), follow-up patency was 94.32% (95% CI, 91.70-96.54), the reintervention rate associated with IBDs was relatively low at 6.96% and buttock claudication was 2.5% [12].

Long-term results are also now available on both the Cook and Gore devices. Primary patency of IIA and EIA for Gore IBE limbs is 95% and 100% respectively and there were no adverse effects like new onset buttock claudication or erectile dysfunction. Freedom from secondary intervention was 90.5% [13]. Significantly, occlusions, if they happened, occurred within the first 30 days. The authors concluded that device occlusions were more likely related to technical or anatomic issues rather than device durability.

Failure modes were also investigated and non-conformation (defined as a decrease in the total iliac index of tortuosity beyond -15%) due to extensive iliac tortuosity (odds ratio 8, $p=0.02$), and IIA diameter of less than 10mm (odds ratio 12, $p=0.02$) were associated with adverse events like endoleak and limb occlusion after iliac branch endoprosthesis deployment [14]. A retrospective study with a follow-up of 4 years compared IBDs to flare limbs for the treatment of CIA aneurysms [9]. This showed that complications like IIA loss, limb thrombosis, and type 1b endoleak appear to be lower for IBDs when compared to flared limbs.

In conclusion, treatment of iliac artery aneurysms should be tailored to the patient. New IBDs show promise and now have long-term durability results. The preservation of the hypogastric artery should be considered for all patients when technically feasible.

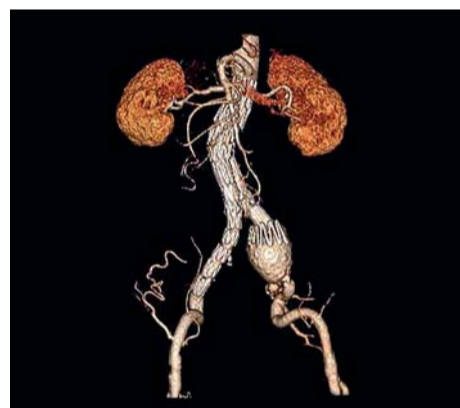


Figure 1: Enlarged iliac artery after an EVAR

Graft type	Endurant™ II	Excluder®	Zenith Spiral-Z®	Alpha Spiral-Z®	E-tegra®
Distal fixation length	≥ 15 mm	≥ 10 mm	> 10mm	> 10mm	≥ 15 mm
Distal fixation diameter	8-25mm	8-25mm	7.5-20mm	8-20mm	8-25mm
Graft size	10-28mm	10-27mm	9-24mm	9-24mm	10-27mm
Sheath size (ID)	14-18Fr	12-15Fr	14-16Fr	12-14Fr	16-19Fr

Table 1: Iliac limbs and manufacturers' IFUs

	Cook Zenith® IBD	Gore Excluder® Iliac Branch Endoprosthesis	Jotec E-iliac®
Aortic to iliac bifurcation length	≥ 50 mm	≥ 50 mm	Not mentioned
CIA diameter	≥ 16 mm	8-25mm	≥ 18 mm
EIA diameter (landing)	8-11mm	6.5-25mm	8-13mm
EIA length (landing)	≥ 20 mm	6.5-13.5mm	≥ 15 mm
IIA length	≥ 10 mm	≥ 16 mm	≥ 15 mm
	(20-30mm preferred)		
IIA diameter	Acceptable for sealing	6.5-13.5mm	Not mentioned
Sheath size	20Fr	16Fr	18Fr
Others	Stainless steel stent	Stainless steel stent	Nitinol stent
		Can be used for isolated iliac aneurysm	Can be used for isolated iliac aneurysms

Table 2: Iliac branch devices

Don't miss it!

Aorto iliac arterial disease
Tuesday, September 13, 10:00-11:00
Auditorium 2



Said Abisi
Guy's and St Thomas' Hospital, London/GB

Dr. Abisi is a consultant vascular and endovascular surgeon at Guy's and St Thomas' NHS Foundation Trust. He has particular expertise in minimally invasive techniques to treat complex aortic conditions, using branched and fenestrated endografts. He has contributed to the introduction and development of new endovascular technology in many national and international centres. He has had numerous publications in renowned scientific journals. He is also an adjunct senior lecturer at the School of Biomedical Engineering & Imaging Sciences at King's College London and is leading research projects on pioneering aortic endografts.



Enming Yong
Tan Tock Seng Hospital, Singapore/SG

Dr. Enming Yong is currently doing a clinical fellowship at St Thomas' Hospital in London. He is a consultant vascular and endovascular surgeon from Tan Tock Seng Hospital, Singapore. He has additional interests in innovation and holds a Master of Business Administration from IE Business School (Spain) and Singapore Management University.

References:

1. Johnston KW, Rutherford RB, Tilson MD, et al. Suggested standards for reporting on arterial aneurysms. Journal of Vascular Surgery 1991; 13: 452-458.
2. Editor's Choice – European Society for Vascular Surgery (ESVS) 2019 Clinical Practice Guidelines on the Management of Abdominal Aorto-iliac Artery Aneurysms – European Journal of Vascular and Endovascular Surgery, [https://www.ejves.com/article/S1078-5884\(18\)30698-1/fulltext](https://www.ejves.com/article/S1078-5884(18)30698-1/fulltext) (accessed 27 July 2022).
3. Ivancev K, Vogelzang R. A 35 Year History of Stent Grafting, and How EVAR Conquered the World. European Journal of Vascular and Endovascular Surgery 2020; 59: 685-694.
4. Pagliaricchio G, Gatta E, Schiavon S, et al. Bell-bottom technique in iliac branch era: mid-term single stent graft performance. CVIR Endovasc 2020; 3: 57.
5. Bosanquet DC, Wilcox C, Whitehurst L, et al. Systematic Review and Meta-analysis of the Effect of Internal Iliac Artery Exclusion for Patients Undergoing EVAR. European Journal of Vascular and Endovascular Surgery 2017; 53: 534-548.
6. Kouvelos GN, Katsargyris A, Antoniou GA, et al. Outcome after Interruption or Preservation of Internal Iliac Artery Flow During Endovascular Repair of Abdominal Aorto-iliac Aneurysms. European Journal of Vascular and Endovascular Surgery 2016; 52: 621-634.
7. The Society for Vascular Surgery practice guidelines on the care of patients with an abdominal aortic aneurysm – PubMed, <https://pubmed.ncbi.nlm.nih.gov/libproxy1.nus.edu.sg/29268916/> (accessed 27 July 2022).
8. Expert Discussion: When to Preserve the Hypogastric Artery – Endovascular Today, <https://evtoday.com/articles/2017-aug-supplement/expert-discussion-when-to-preserve-the-hypogastric-artery> (accessed 27 July 2022).
9. Pini R, Faggioli G, Indelicato G, et al. Early and Late Outcome of Common Iliac Aneurysms Treated by Flared Limbs or Iliac Branch Devices during Endovascular Aortic Repair. Journal of Vascular and Interventional Radiology 2019; 30: 503-510.
10. Torsello G, Schönfeld E, Osada N, et al. Endovascular Treatment of Common Iliac Artery Aneurysms Using the Bell-Bottom Technique: Long-term Results. Journal of Endovascular Therapy 2010; 17: 504-509.

Don't miss it!**Shaping the future of IR**

Wednesday, September 14, 11:00-12:00
Room 112

Recognition of IR as a specialty – challenges

Michael Lee



Michael Lee
RCSI University of Medicine
and Health Sciences,
Dublin/IR

Prof. Lee is currently a fellow of the Royal College of Physicians in Ireland. He graduated from medical school in Dublin in 1982 before discovering an interest in interventional radiology during his time as a trainee. He went on to pass the Boards of Radiology in both Ireland and the UK in 1989 and completed fellowships at Massachusetts General Hospital and at Harvard Medical School before returning to Ireland in 1995 as a Professor of Radiology.

Prof. Lee has published prolifically. He has written nearly 200 peer-reviewed publications and has edited or authored multiple chapters and textbooks. He has given more than 200 lectures around the world and is a committed educator, introducing an eight-hour IR teaching curriculum to the Royal College of Surgeons Ireland that ensures medical students are now taught about IR at an early stage in their career.

Prof. Lee has held many positions in national and international societies. Among many others, he was the first president of the Irish Society of Interventional Radiology and was President of CIRSE from 2011-2013. He was also a CIRSE Gold Medallist in 2016.

Interventional radiology (IR) is unique in medicine, as it requires a triumvirate of competencies, which include imaging competency, procedural/surgical competency and competency in clinical care. As interventional radiology work practices have changed, new treatments have become available, knowledge has grown and the scope of practice including the aforementioned competencies, knowledge and skills have now become distinctly different to diagnostic radiology. There is no doubt that these changes in IR over the last twenty years, supported by major new concepts in IR science, new IR skills, advances in technology, new techniques and equipment as well as specialist continuing professional development and research, have transformed this area of medicine into a distinct practice deserving of specialty status.

Professor Colin Cantwell (Saint Vincent's University Hospital Dublin) and I, along with other IRs, embarked on a process to achieve specialty status for IR in Ireland in 2020. The application process to the Irish Medical Council (the responsible body) is long, arduous and time consuming. We are currently at the end of stage one hoping to progress into stage two (Figure 1 a-c). The process is complex and a wide variety of consultations with post graduate training bodies, other faculties of medicine and surgery, the Dept. of Health and the National Training Programme Directorate are all necessary. Public engagement is also mandatory.

The main planks of our submission were:

Patient safety: The lack of 24/7 IR on-call services throughout the country is a significant risk to the public.

Equity of access: All patients should have access to interventional radiology for consultations regarding elective procedures.

Dedicated training programme: interventional radiologists and the public deserve to have a ring fenced training programme for appropriate training in

imaging, clinical practice and IR techniques to develop the skills and competencies required to practice IR to the highest level. The IR training programme should have both formative and summative assessment and should last a minimum of two years.

Workforce planning: A model of care (MOC) document for IR throughout Ireland was developed looking at the numbers of IRs and the numbers of procedures and benchmarking those to numbers from other European countries. This model of care document allows us to benchmark our service against IR services in other countries and also to plan for the new posts required to support a countrywide 24/7 on call and replace retirees. The MOC is a vital piece of any application.

The challenges we face are many and are listed below:

1. Limited formal recognition of IR as a specialty within other EC countries.
2. Fragmentation of existing diagnostic radiology services from an on-call and DR workload point of view.
3. Is there data detailing cost benefit analysis for IR? This is a difficulty, as there are limited studies on cost benefit analysis for IR.
4. The recognition of IR as a specialty and any training programme must comply with article twenty-five of Directive 2005/36/EC on the recognition of professional qualifications and regulation.
5. Lots of politics involved!

However, despite the above challenges, the most heartening outcome has been the immense support from surgical services, acute care services including critical care, anaesthesiology and emergency medicine as well as all the other medical faculties. Support also came from the Dept. of Health in Ireland, the NDTP (National Doctors Training and Planning, the body in charge of all of the medical and surgical training programmes in Ireland) and the health services executive. There was also wide engagement and support from patients and the public.

Although the challenges listed above can be overcome, there are certain key elements that one must have before embarking on this process, including:

1. Support from the diagnostic radiology training body, who are the recognised body in charge of radiology training or equivalent in your country.
2. A model of care document to outline workforce planning for the next ten to twenty years.
3. A commitment from the national radiology training body in your country to support a dedicated curriculum based IR training programme for at least two years with formative and summative assessment.
4. Letters of support from patient groups, other specialties, health authorities and training bodies
5. There is an immense amount of writing and supporting documents to procure and collate, which takes time.
6. A team of dedicated and enthusiastic interventional radiologists who will spend immense amounts of time on the project.

IR is now on the crest of a wave, and I believe there is immense goodwill toward IR from other specialties that we need to take advantage of and start the process of applying for specialty status. I will leave you with the words of Shakespeare from "Julius Caesar":

"There is a tide in the affairs of men, which taken at the flood, leads on to fortune. Omitted, all the voyage of their life is bound in shallows and in miseries. On such a full sea we are now afloat, and we must take the current when it serves. Or lose our ventures".

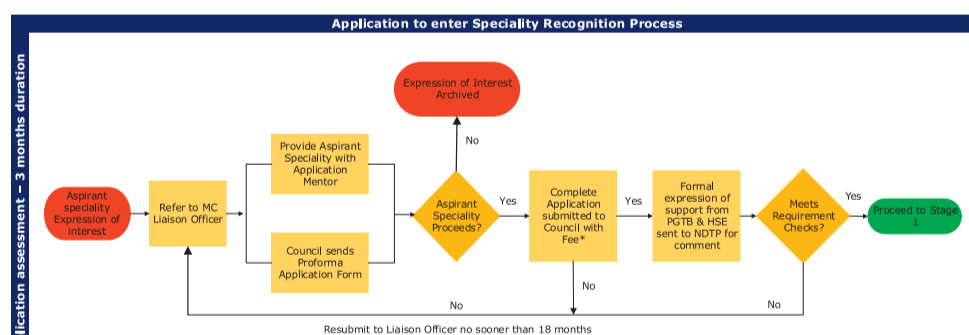


Figure 1a: Letter of intent

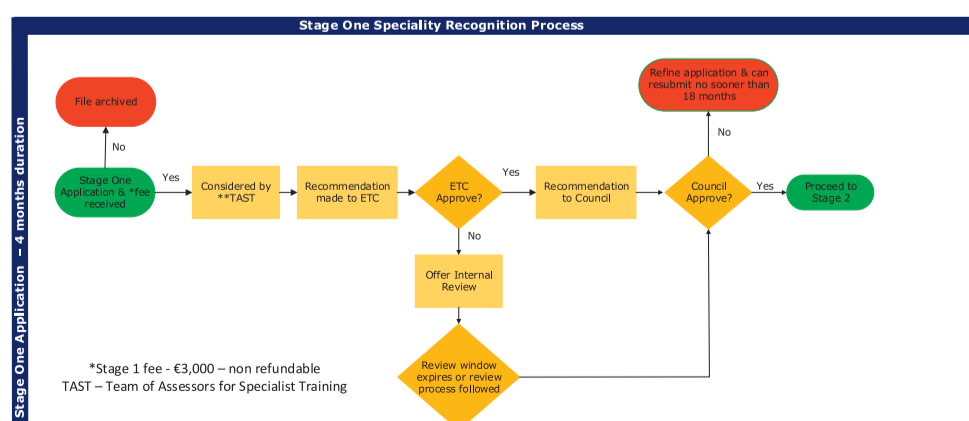


Figure 1c: Stage 2

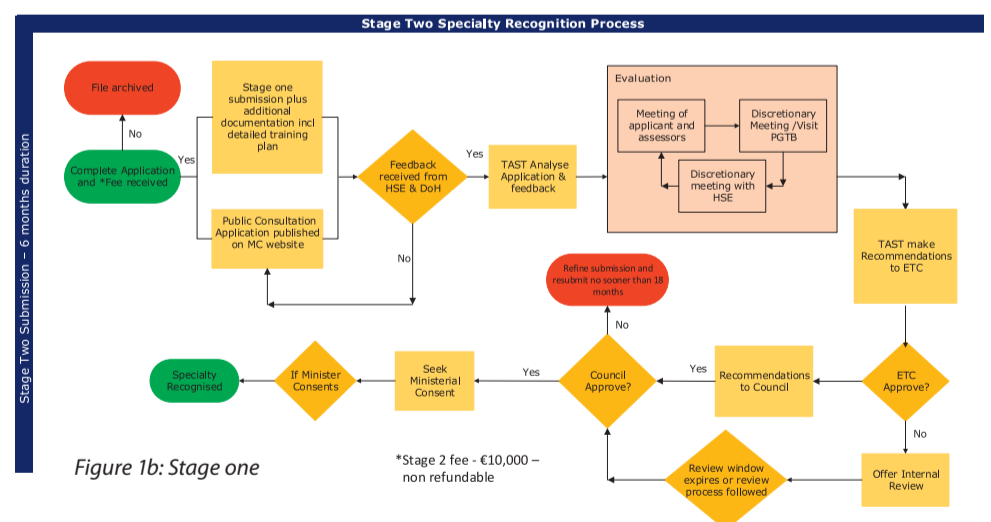


Figure 1b: Stage one

Embolisation in bleeding: stent-graft

Sara Protto

Minimally invasive endovascular interventions for treating acute bleeding have become widely adopted in the last decades due to advances in technology that have enabled a radical expansion of indications [1].

Independent of the site and etiology of the bleeding, spontaneous, iatrogenic or traumatic, the endovascular approach is a treatment alternative that has proven to be fast, safe and effective. The use of endovascular techniques obviates the need for surgical exploration, reducing morbidity and mortality. Angiography can also be used as a diagnostic tool followed by swift treatment of the bleeding [2]. However, in the majority of cases, if the patient is stable, computed tomography angiography (CTA) should be used to evaluate the source of bleeding, helping in the planning of patient management [3] (Fig. 1).

An interventional radiologist has many different tools to treat arterial injuries, which can be divided into two main categories:

1. Embolisation materials (particles, coils, plugs, and liquid embolics), which usually lead to complete occlusion of the vessel
2. Stent-grafts, i.e., metallic intravascular stents covered with a fabric of either expanded polytetrafluoroethylene (ePTFE) or Dacron, which preserve the arterial patency (Fig. 2)

Thus, it is essential to learn which device/ embolic material should be preferred in different cases to achieve the best result.

The first step is to decide if the injured artery can be sacrificed. Arteries with ample collateral circulation can usually be occluded without causing ischaemic damage to the vascularised structures. On the other hand,

patency should be preserved in case of a main supplying artery, such as the carotid, hepatic, or superficial femoral artery.

Once the stent-graft approach has been chosen, the second step would be to pick between a balloon-mounted or self-expanding stent. The first one is mounted over a percutaneous transluminal angioplasty (PTA) balloon, which allows the precise deployment, i.e. near a bifurcation or vessel origin. However, the delivery system is quite rigid and more difficult to navigate in tortuous vessels; thus, it is usually deployed in large or medium-sized vessels. The self-expanding stent is sheathed in a retractable delivery system; the deployment is less precise and has to be monitored under fluoroscopy. Moreover, some stents can shorten during deployment; consequently, a longer size may have to be preferred. The delivery system is more flexible, allowing this device to be used in vessels that are more tortuous and in the extremities near the joints (Fig. 3). To reach sufficient sealing and wall apposition, the oversizing of a self-expandable covered stent should be at around 20%.

The use of a stent-graft is an effective method to treat pseudoaneurysms, extravasation, dissection flaps, arteriovenous fistulae, and partial or complete transection while preserving the patency of the injured vessel (Fig. 4). Those injuries are often seen in trauma patients with the specific characteristics depending on the mechanism of the trauma, i.e. whether it is direct or indirect blunt trauma or direct penetrating trauma. However, 30-40% of peripheral vascular injuries are iatrogenic and the possibility to treat those lesions endovascularly is especially appealing [4]. In addition, a major advantage of using minimally invasive techniques is the possibility to treat using percutaneous distant access under local

anesthesia, thus avoiding the risks of open surgery [5].

Regardless of the site of the lesion, the procedure has to be planned carefully using contrast-enhanced multidetector computed tomography (MDCT) and multiplanar reformatting with maximum intensity projection (MIP). Evaluation of the diameter and length of the injured vessel segment is of central importance when planning the sizing of a peripheral stent-graft device, the access site, and the possible use of a closure device (Fig. 5).

After the procedure, the most common complications are access-site bleeding, acute or delayed stent thrombosis, stent fracture and infection. The clinical presentation in the case of early or late stent occlusion depends on the location of the stent. Especially in small diameter arteries, the risk of thrombosis is high. In some occasions, acute occlusion can lead to catastrophic outcomes, such as in the case of carotid artery stenting; thus, single or dual antiplatelet therapy should be taken into consideration.

References:

1. Nicholson AA. Vascular radiology in trauma. *Cardiovasc Intervent Radiol.* 2004 Mar-Apr;27(2):105-20. doi: 10.1007/s00270-003-0031-z. PMID: 15259804.
2. Peynircioğlu B, Ergun O, Hazirolan T, Serter T, Uçar I, Cil B, Cekirge S. Stent-graft applications in peripheral non-atherosclerotic arterial lesions. *Diagn Interv Radiol.* 2008 Mar;14(1):40-50. PMID: 18306145.
3. Rieger M, Mallouhi A, Tauscher T, Lutz M, Jaschke WR. Traumatic arterial injuries of the extremities: initial evaluation with MDCT angiography. *AJR Am J Roentgenol.* 2006 Mar;186(3):656-64. doi: 10.2214/AJR.04.0756. PMID: 16498092.
4. Ruppert V, Sadeghi-Azandaryani M, Mutschler W, Steckmeier B. Gefäßverletzungen an den Extremitäten [Vascular injuries in extremities]. 2004 Dec;75(12):1229-38; quiz 1239-40. German. doi: 10.1007/s00104-004-0965-y. PMID: 15536512.
5. Katsanos K, Sabharwal T, Carrell T, Dourado R, Adam A. Peripheral endografts for the treatment of traumatic arterial injuries. *Emerg Radiol.* 2009 May;16(3):175-84. doi: 10.1007/s10140-008-0771-9. Epub 2008 Oct 22. PMID: 18941810.
6. Mahnen AH, Althoff P, Frink M, Viniol S. Interventionelles Management peripherer Gefäßverletzungen: Von der Ausnahmeindikation zum Verfahren der 1. Wahl [Interventional management of peripheral vascular injuries: From the exclusion indication to the procedure of first choice]. 2021 Aug;124(8):635-641. German. doi: 10.1007/s00113-021-01029-z. Epub 2021 Jun 29. PMID: 34189587.

Don't miss it!

Embolisation in bleeding: which material for which lesion

Tuesday, September 13, 16:15-17:15
Room 114



Sara Protto
Tampere University
Hospital, Tampere/Fl

Dr. Sara Protto is an interventional radiologist based in Finland at Tampere University Hospital. She received her medical degree from the University of Pavia in 2007 and completed her radiology training in 2014 at Tampere University Hospital. During her residency, she has received a CIRSE grant and had the possibility to work in Klagenfurt with Prof. Klaus Hausegger.

In 2019, she received the subspecialty in IR from the Finnish IR society and the EBIR. She has been actively involved in the European Trainee Forum, where she served as deputy chairperson between 2018 and 2020, focusing on promoting IR between students and a particular interest in encouraging women to undertake this career.

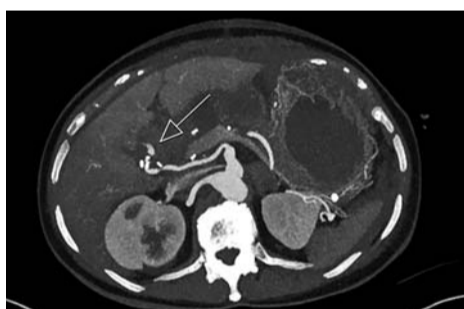


Figure 1: Hepatic artery bleeding (CTA)



Figure 2: Example of stent-graft

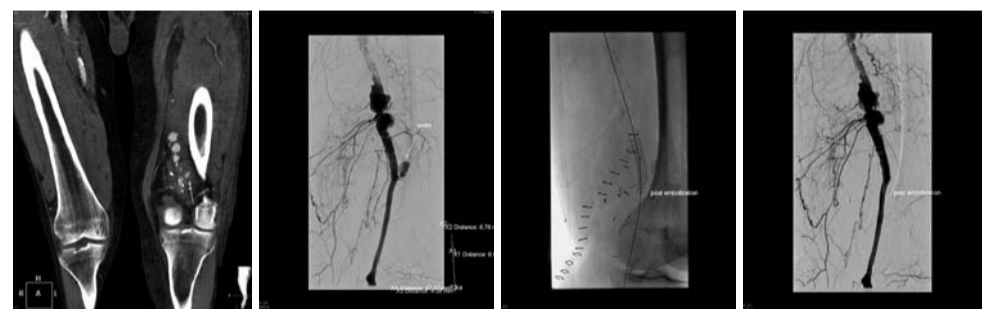


Figure 3: 72-year-old man. Popliteal aneurysm open surgery repair, one week later patient arrives in the ER with swallowed knee and at US 5x5x10 cm hematoma. (a) CT showing bleeding at the upper anastomosis, (b) Angiography showing the bleeding, (c,d) Post-deployment angiography, Viabahn 8x50 mm.

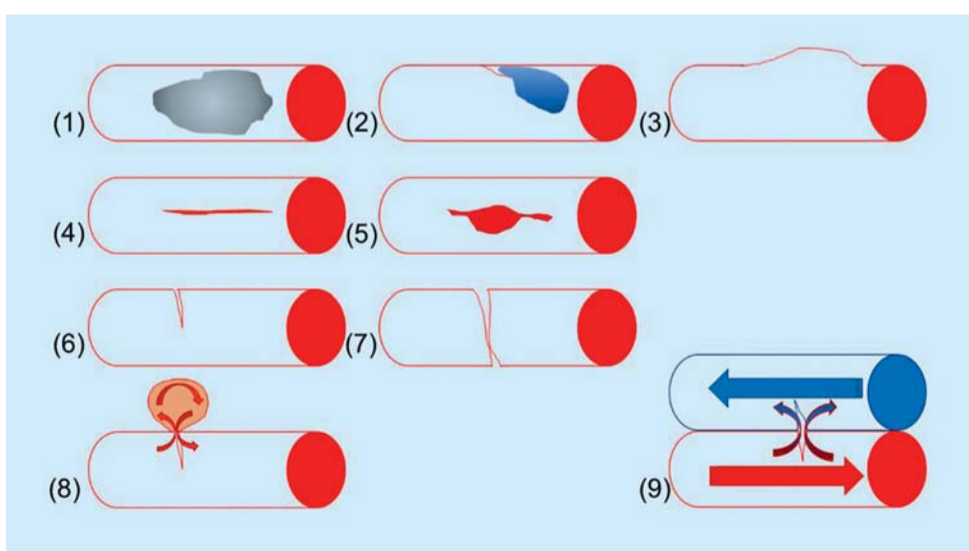


Figure 4: Schematic representation of typical arterial vessel injuries: (1) simple contusion, (2) contusion with intimal injury and thrombosis, (3) contusion with secondary aneurysm, (4) simple laceration, (5) laceration with partial wall loss, (6) incomplete transection, (7) complete transection, (8) pseudoaneurysm, and (9) arteriovenous fistula [6].

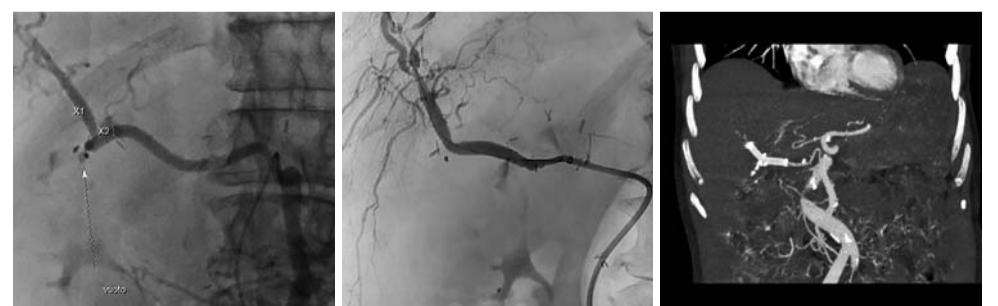
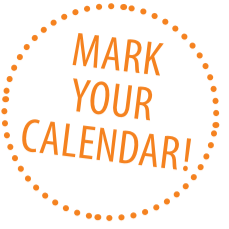
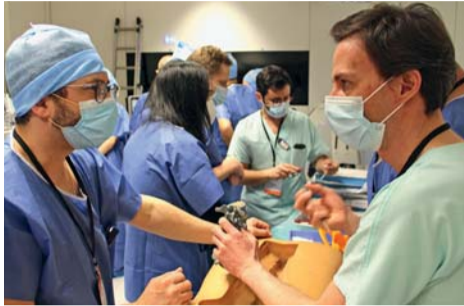Figure 5: 72-year-old woman one month post Whipple, (a) bleeding of a branch of the right hepatic artery, which originated from the SMA, (b) Post-deployment angiography, Viabahn 6mm x 50mm (c) Control CTA 2 months later.



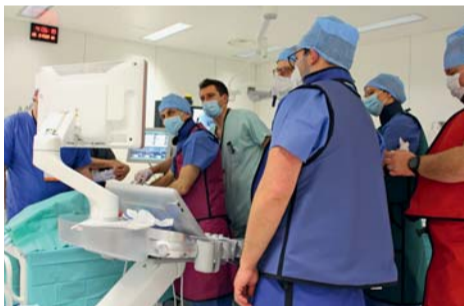The European School of Interventional Radiology is back!

The European School of Interventional Radiology has been providing premier and therapy-focused educational programmes for IR professionals since 2006, helping participants stay up to date on a variety of procedures with 117 courses held in 24 countries to date.



After a two-year break due to the pandemic, the ESIR finally saw a return to its collaborative, face-to-face courses with its first 2022 instalment on ablation held at the Institute of Image-Guided Surgery in Strasbourg, France in February. The course provided an overview on all currently available ablation technologies and featured the discussion of technically challenging cases. In addition, participants were able to fine-tune their practical skills in the animal lab.

In March, the ESIR travelled to Harlow, UK for a course on the multidisciplinary endovenous management of varicose veins, varicocele, and pelvic congestion. Organised by Dr. Zaid Aldin and the endovascular team at the Princess Alexandra Hospital, attendees learned about the fundamentals and various techniques through lectures from expert faculty members and hands-on experience opportunities.



In May, 37 participants from around the globe participated in the ESIR course on TACE in primary and secondary liver cancer. Dr. Tobias Jakobs and his team hosted the course at the Barmherzige Brüder hospital in Munich, Germany. Over two days, participants and faculty members engaged in a comprehensive discourse on the staging and treatment algorithm of HCC and metastatic liver disease via lectures, discussions, the analysis of interesting video cases, and various hands-on workshops including simulators.

Upcoming courses

Radioembolisation of Liver Tumours Utrecht/NL, Nov. 3-4, 2022

In the upcoming course on radioembolisation of liver tumours organised by Dr. Maarten Smits, Dr. Arthur Braat and Prof. Marnix Lam, attendees will learn about the fundamentals of the field, the latest evidence, and various techniques. Throughout the hands-on workshops of the course, participants will be able to familiarise themselves with a wide range of techniques and products. As always, there will be plenty of opportunities for discussions with the experts and networking with colleagues from around the world.

Hands-On Liquid Embolisation Strasbourg/FR, Nov. 17-18, 2022

In recent years, liquid embolics have increased in popularity among interventional radiologists. However, as the management and technical aspects of liquids vary quite significantly from that of conventional coils or particles, the learning curve is difficult. It is therefore recommended to gain first experience in the animal lab. In this unique course, pigs will be used in in-vivo workshops for attendees to learn how to deal with the injection of glue and EVOH into livers and kidneys. In the ex-vivo workshops, participants will practice on models to learn about the right way to use sclerosants, cyanoacrylate glue, and EVOH. Additional parallel stations will provide opportunities for participants to learn about the preparation and mixing of glue and EVOH. Organised by Prof. Christoph Binkert and led by a team of expert faculty members, this course will ensure that experienced IRs are up to date on this important and expanding facet of embolisation. Spaces are limited, so secure your spot today!

Reliability in Percutaneous Tumour Ablation Innsbruck/AT, Dec. 15-16, 2022

Thermal ablation has been proven to be an effective method for the treatment of numerous tumour entities in various anatomical locations and has great potential to increasingly replace open or laparoscopic resection. In order to achieve maximal reliability, however, interventional oncologists must be properly trained in the application of the various available tools, imaging techniques and image fusion tools. This ESIR course organised by Prof. Reto Bale will give attendees an overview of the currently available devices and techniques in the, enabling them to plan and perform procedures and conduct the corresponding follow-up. The Innsbruck course has proved popular in the past years, so make sure to register today!

"The ESIR course on ablation from A-Z in Strasbourg was an amazing experience, with solid practical and theoretical information in terms of management of patients before, during, and after ablation. Being among people so passionate and enthusiastic about their work has been such an inspirational and motivational experience; this course made me feel that I have learned a lot and, at the same time, had fun. Don't think about it twice and be part of the next courses!"

Dr. Flavio Andresiani
University Hospital Campus Bio-Medico
Rome/IT

"Being part of the ESIR course on TACE in primary and secondary liver cancer was an incredible experience. Gaining information about the latest data and technologies from all the renowned experts in the field and being able to practice at the hands-on sessions was a great opportunity. One of my favourite things about the course was the live cases, where you got to see all the different approaches and how to deal with potential complications. I think you can learn a lot from the faculty's worst complications lectures. I think I will benefit greatly from the presenters' expertise and networking with other doctors from all over Europe."

Dr. Sophia Holzhauser
Resident at Barmherzige Brüder Hospital
Munich/DE

"The ablation course was a unique learning experience. Our local host Prof. Gangi was a great mentor and teacher. The presentations ranged from intermediate to advanced level, and there were many opportunities to interact with different international colleagues, some more experienced than others. Hands-on training with local professionals was a great way to learn many techniques. Looking forward to my next course in Utrecht and many more to come in the near future."

Dr. Maurizio Moojen
Leiden University Medical Centre
Leiden/NL

ESIR will offer even more courses in 2023

Critical limb ischaemia Florence, Italy, February 9-10

Local Host: F. Fanelli
Venue: Careggi University Hospital –
University of Florence

Ablation from A-Z: liver and kidney Strasbourg, France, February 23-24

Local Host: A. Gangi
Venue: Institute of Image-Guided Surgery
Strasbourg

Prostate embolisation Milan, Italy, March 23-24

Local Host: A.G. Rampoldi
Venue: AIMS Academy – Ospedale Niguarda
Ca'Granda

Non-liquid embolisation from A-Z Strasbourg, France, May 25-26

Local Host: R. Iezzi, P. Lucatelli
Venue: Institute of Image-Guided Surgery
Strasbourg

Portovenous interventions of the liver Düsseldorf, Germany, June 15-16

Local Host: P. Minko
Venue: University Hospital Düsseldorf

Thyroid thermal ablation Milan, Italy, TBA

Local Host: G. Mauri
Venue: European Institute of Oncology

Ablation from A-Z: lung and MSK Strasbourg, France, October 19-20

Local Host: A. Gangi
Venue: Institute of Image-Guided Surgery
Strasbourg

Liquid embolisation from A-Z Strasbourg, France, November 16-17

Local Host: C. Binkert
Venue: Institute of Image-Guided Surgery
Strasbourg

Acute ischaemic stroke intervention Maribor, Slovenia, December 6-7

Local Host: J. Lučev, S. Breznik
Venue: University Medical Centre Maribor



Percutaneous RF-based arteriovenous fistula creation

Panagiotis M. Kitrou

Percutaneous arteriovenous fistula (AVF) creation is an innovative way of creating a vascular access for hemodialysis without the need for surgical incisions, sutures, and scars as is the case of surgically created AVFs (Figure 1). Understanding the concept goes beyond the procedure itself and extends to the right patient selection as well as to the proper training for cannulating these AVFs. The video learning session (VL 3003 – Vascular interventions), will clarify the process of correct patient selection via ultrasound screening and a recorded case of an RF-based pAVF (WavelinQ™ EndoAVF system) will be shown.

In an RF-based AVF creation, the anastomosis is created by connecting the radial artery or the ulnar artery with one of their accompanying concomitant veins. The system is composed of two 4Fr catheters (arterial and venous) carrying magnets, while the venous catheter holds the electrode that will give a 60-watt pulse for 0.7 seconds to create the anastomosis (1).

With the anastomosis created in the deep venous system of the forearm and the future cannulation zone at the superficial system of the arm (cephalic or basilic vein), the main prerequisite for this AVF to function is the perforating vein at the level of the elbow which diverts the blood from the deep to the superficial system (Figure 2). Other prerequisites include, but are not limited to, the size of the vessels at the level of the anastomosis having a minimum diameter of 2 mm and the diameter of the perforating and the superficial vein being a minimum of 2.5 mm.

It becomes apparent that in order to perform the procedure, one should be familiar with the ultrasonographic anatomy of the region in

order to evaluate the patient during the vessel mapping, as well as with the angiographic anatomy as the procedure is fluoroscopy guided (Figure 3,4).

The procedure can be performed under local anesthesia, but an axillary nerve block is recommended as it provokes vasodilation which is important for vessel access. Due to device symmetry, access can be gained both in a parallel and an antiparallel manner, meaning that the vein and the artery can be both accessed from the wrist or the brachial region, or alternatively, one catheter from the brachial and one from the wrist region (Figure 5). The selection/planning of the vessel access is solely based on proper ultrasound screening. Frequently, more than one option is available. An important intraprocedural element is the decision of coiling one of the brachial veins at the index procedure. Coiling allows easier blood diversion from the deep to the superficial system, thus facilitating superficial venous maturation of the cannulation zone and reducing future re-interventions.

The data so far suggest high technical success, minimum complication rates and a low number of interventions needed to assist maturation and maintain patency of the vascular access circuit (2-8). It should be pointed out, however, that the number of cases available in the published literature is still low and comes from experienced users. It remains to be proven whether these results will be confirmed moving from “study cases” to “real-life cases”.

An important part of the discussion regarding percutaneous AVFs, in general, is the comparison with the surgical AVFs regarding outcomes as well as cost (9-11). With the deep venous system of the forearm

used for the anastomosis, percutaneous AVFs offer additional anastomotic options to the haemodialysis patient and are, thus, complementary to the surgical options rather than antagonistic. As with every new technology, skepticism is legitimate on the one hand, while the arguments about comparisons seem fallacious on the other. Last but not least, due to the lack of long-term follow-up and amassed data, percutaneous AVFs have not yet found their place in the algorithmic approach of vascular access creation. Based on the site of the creation, the principle of not compromising future options and common sense, an attempt has been made to position percutaneous AVFs between radio-cephalic and brachio-cephalic fistulas. But evidence is still missing.

The fundamental reason for the use of new devices and the implementation of new procedures is the aim for improved outcomes and improved quality of life of patients. Percutaneous AVFs have made great strides along this route.

References:

1. Kitrou PM, Balta L, Papachristou E, Papisotiriou M, Katsanos K, Theofanis M, et al. Percutaneous Arteriovenous Fistula Creation with the WavelinQ 4-French EndoAVF System: A Single-Center Retrospective Analysis of 30 Patients. *J Vasc Interv Radiol.* 2022;33(1):33-40.
2. Berland TL, Clement J, Griffin J, Westin GG, Ebner A. Endovascular Creation of Arteriovenous Fistulae for Hemodialysis Access with a 4 Fr Device: Clinical Experience from the EASE Study. *Ann Vasc Surg.* 2019;60:182-92.
3. Rajan DK, Ebner A, Desai SB, Rios JM, Cohn WE. Percutaneous creation of an arteriovenous fistula for hemodialysis access. *J Vasc Interv Radiol.* 2015;26(4):484-90.
4. Lok CE, Rajan DK, Clement J, Kiaii M, Sidhu R, Thomson K, et al. Endovascular Proximal Forearm Arteriovenous Fistula for Hemodialysis Access: Results of the Prospective, Multicenter Novel Endovascular Access Trial (NEAT). *Am J Kidney Dis.* 2017;70(4):486-97.
5. Radosa CG, Radosa JC, Weiss N, Schmidt C, Werth S, Hofmocker T, et al. Endovascular Creation of an Arteriovenous Fistula (endoAVF) for Hemodialysis Access: First Results. *Cardiovasc Intervent Radiol.* 2017;40(10):1545-51.
6. Shahverdyan R, Beathard G, Mushtaq N, Litchfield TF, Nelson PR, Jennings WC. Comparison of Outcomes of Percutaneous Arteriovenous Fistulae Creation by Ellipsys and WavelinQ Devices. *J Vasc Interv Radiol.* 2020;31(9):1365-72.
7. Zemela MS, Minami HR, Alvarez AC, Smeds MR. Real-World Usage of the WavelinQ EndoAVF System. *Ann Vasc Surg.* 2021;70:116-22.
8. Berland T, Clement J, Inston N, Kreinberg P, Ouriel K, Wavelin QF. Percutaneous arteriovenous fistula creation with the 4F WavelinQ EndoAVF System. *J Vasc Surg.* 2022;75(3):1038-46 e3.
9. Inston N, Khawaja A, Tullett K, Jones R. WavelinQ created arteriovenous fistulas versus surgical radiocephalic arteriovenous fistulas? A single-centre observational study. *J Vasc Access.* 2020;21(5):646-51.
10. Rognoni C, Tozzi M, Tarricone R. Endovascular versus surgical creation of arteriovenous fistula in hemodialysis patients: Cost-effectiveness and budget impact analyses. *J Vasc Access.* 2021;22(1):48-57.
11. Arnold RJG, Han Y, Balakrishnan R, Layton A, Lok CE, Glickman M, et al. Comparison between Surgical and Endovascular Hemodialysis Arteriovenous Fistula Interventions and Associated Costs. *J Vasc Interv Radiol.* 2018;29(11):1558-66 e2.

Don't miss it!

Vascular interventions

Tuesday, September 13, 16:15-17:15
Room 115



Panagiotis M. Kitrou
Patras University Hospital
Patras/GR

Dr. Panagiotis M. Kitrou is an assistant professor of interventional radiology in the department of diagnostic and interventional radiology at Patras University Hospital in Greece. Dr Kitrou's scientific interests include vascular access, PAD, and interventional oncology. He has published more than 70 scientific papers and has been nominated for the Editor's Award for Distinguished Clinical Study in Vascular and Interventional Radiology by JVIR in 2015 and 2017. He is the Meeting Director of the EVA (Endo Vascular Access) Meeting.


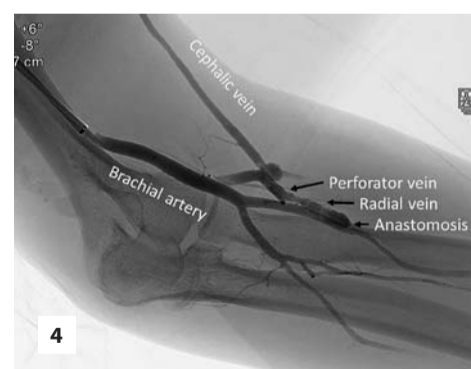
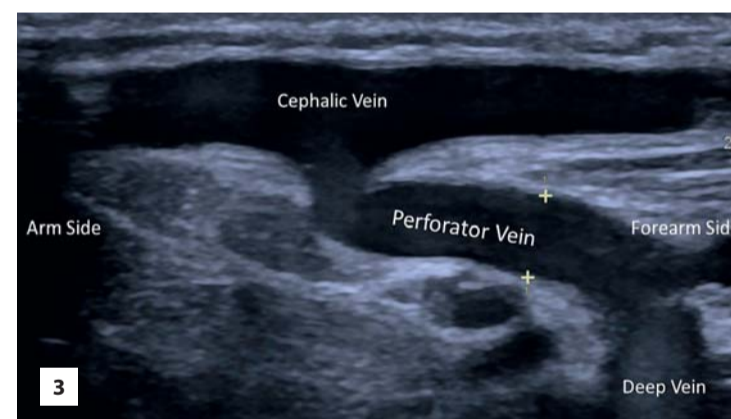
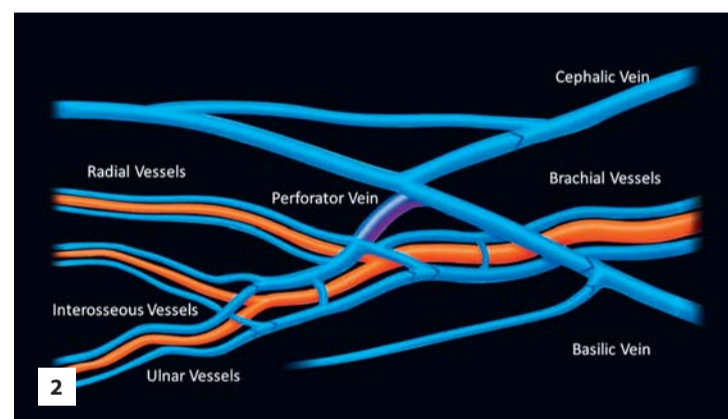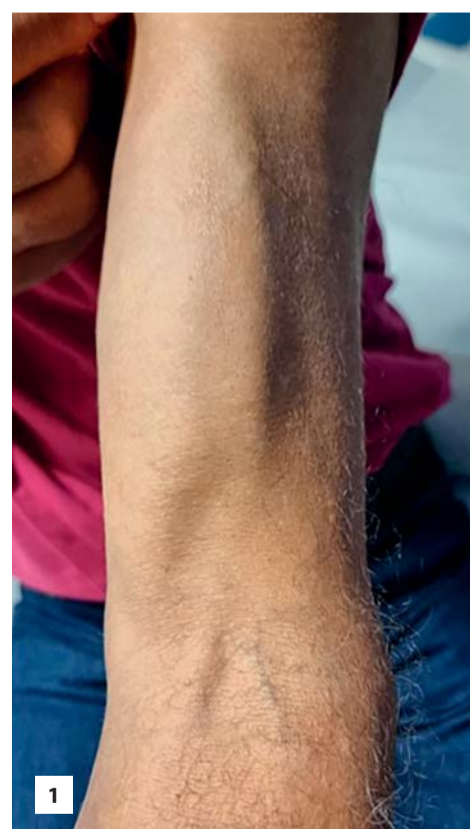


Figure 1: A percutaneous RF-based created arteriovenous fistula

Figure 2: Schematic representation of the vasculature around the elbow region

Figure 3: Longitudinal ultrasound showing the vascular connection between the deep and the superficial venous system via the perforator vein at the level of the elbow

Figure 4: Fluoroscopic image of a final fistulogram following a percutaneous AVF creation. The different components of the vascular access circuit are shown (following the direction of blood flow: Brachial artery, radial artery, anastomosis, radial vein, perforator vein, cephalic vein)

Figure 5: Different catheters alignments. Parallel alignment with brachial access (A), with wrist access (B), and antiparallel alignment with wrist and brachial access (C). White arrows show the direction of the catheter which can be figured out by the indicators on it, which are placed near the tip (white stars)

Publishing with CVIR Endovascular: The author experience

CVIR ENDOVASCULAR

CVIR Endovascular is CIRSE's open-access journal set up to cater to the increasing amount of endovascular research and in response to the previous lack of publication possibilities for researchers. It was launched in September 2017, with its first articles published in June 2018. Since then, more than 300 articles have been published, triggering over 350,000 article downloads.

We spoke with some authors who have recently published their research in CVIR Endovascular to find out about their experience.

Corresponding and first author



Gerard M. Healy
St Vincent's University
Hospital, Dublin, Ireland



Paper

Proctalgia secondary to rectal arteriovenous malformation and inferior mesenteric vein stenosis in a patient post liver transplant

Twitter: @ger_healy

Can you tell us a little bit about the paper you published in CVIR Endovascular?

Healy: The case report I submitted describes a patient with chronic proctalgia, a condition which significantly impacted his quality of life. He underwent multiple treatments including opioids, nerve blocks and surgical intervention, but symptoms did not improve. When reviewed at a multi-disciplinary meeting, our senior author (Dr. Jeff McCann, Consultant IR at St Vincent's University Hospital, Dublin) identified a rectal arterio-venous malformation (AVM) on CT, which was suspected to be the cause of the patient's symptoms. Further review of prior imaging demonstrated progressive stenosis and ultimate occlusion of the outflow vein (inferior mesenteric vein), which coincided with the onset of symptoms. Intimal hyperplasia causing outflow vein stenosis/occlusion are associated with the development of symptomatology in AVMs. This AVM was successfully treated with embolisation using absolute alcohol, leading to the resolution of the patient's symptoms.

This case is a great example of how minimally invasive therapies delivered by interventional radiology can have a major impact on a patient's quality of life. It also highlights the value that interventional radiologists can bring to multi-disciplinary teams managing patients with complex problems, offering both diagnostic and therapeutic expertise to patient care.

Communication of new technologies and short communications have always been the cornerstone of the growth of interventional radiology. Do you think there are currently enough easily accessible interventional radiology publication possibilities for case reports, short communications, technical notes etc.?

Healy: From my experience, it is quite challenging to publish case reports in IR, due to the limited number of suitable journals and high number of submissions. I believe that CVIR Endovascular has provided a much-needed addition to this space.

What is your experience with open access? How did you experience the editorial handling experience in CVIR Endovascular?

Healy: I found the editorial process to be excellent on all occasions, with short waiting times, valuable comments from reviewers and fast publication once accepted. It was also very interesting to know the reviewer names! I hope that open access will continue to grow over the coming years. I believe that open access is best for our patients, since information can be rapidly and widely disseminated without a paywall barrier. This is important for me, since I believe that improving patient outcomes/experience is at the centre of everything an IR does, regardless of whether they are working in the angiographic lab or the research lab.

Impact factor is still an important scientific parameter in many institutions, although other parameters like citation index are becoming more important. How is this in your institution and what is your opinion about it?

Healy: No metric is perfect and I feel that many institutions place too much worth on these numbers. My institution does not focus overtly on any of these metrics. However, I am aware from discussions with international colleagues that impact factor is the most commonly used parameter for academic advancement. I feel that citation index is potentially a more accurate measure of a researcher's contribution to the literature compared to impact factor, since it accounts for both the number of publications and citations that an individual researcher has achieved to date, rather than focusing on the 'prestige' of the journal they have published papers in. One drawback of citation index is that it is slow, since it typically takes a year or more for publications to accumulate citations.

In the shorter term, measuring digital attention (e.g. likes, mentions, shares, comments, bookmarks, traditional citations), using platforms such as Altmetric Attention Score (AAS) or Plum X, can give an early indication of the interest that is generated by an individual publication or preprint. However, many consider that these measurements are tracking the social impact more than the scientific impact of the publications, hence I feel that measuring digital attention should be considered complementary to impact factor, rather than a replacement.

Young scientists find it more and more difficult to get their first paper published. Do you think that CVIR Endovascular can play a role in alleviating the situation?

Healy: I agree that it is difficult for young scientists to get their first paper published. CVIR Endovascular provides excellent workshops which are opportunities for young researchers to learn and increase their chances of successful submissions. In addition, the reviewer forum is available for young scientists to learn this important skill in a stepwise manner.

Would you consider submitting your scientific work to CVIR Endovascular again and if so, why?

Healy: Certainly. The efficient editorial process and target audience make this one of the ideal journals for me to submit my work to in future.

2022 award winner for the article with the best media performance

Corresponding and first author



Kensaku Mori
University of Tsukuba,
Tsukuba, Japan



Paper

"Pigtail through snare" technique: an easy and fast way to retrieve a catheter fragment with inaccessible ends

Can you share a little about your paper?

Mori: Our paper proposed a fast and easy alternative method, the "Pigtail through snare" technique, which passes a pigtail catheter through an opened snare loop in advance, pulls the free end into the snare loop with the pigtail catheter, and snares it immediately. With this method, you do not have to move the snare catheter because the free end falls into the snare loop automatically by pulling the pigtail catheter.

Do you think there are enough IR publication possibilities for case reports, short communications, technical notes etc.?

Mori: In recent years, a decreasing number of journals worldwide are accepting case reports, short communications, and technical notes due to the increased total number of submitted manuscripts. Thanks to CIRSE's launch of the open access journal CVIR Endovascular, we have more opportunities to share interesting case reports and tips, like our technical note in interventional radiology.

How is impact factor used in your institution and what is your opinion about this metric?

Mori: At our institution, the impact factor is mainly used to evaluate the academic achievements of researchers, although recently the citation index of individual papers is also being evaluated. In my opinion, the citation index and other new metric parameters can be used to evaluate individual papers and to introduce attractive papers to readers.

Do you think that CVIR Endovascular offers a good opportunity for young scientists to get their first papers published?

Mori: Since becoming a faculty member at the university hospital, I have recommended that young doctors aspiring to IR first write a case report. I tell them that writing a case report about the treatment of rare conditions and new procedural ideas will help other patients in the same situation worldwide. The aims and scope of CVIR Endovascular fit perfectly with this purpose and provide young interventional radiologists with an entrance to our community.

Would you consider submitting your future work to CVIR Endovascular again?

Mori: Of course, I will. The main reason being that it is an open-access journal and can be read without imposing a financial burden on its readers. I believe that submitting papers to this journal will help more IR colleagues worldwide as well as the patients they treat.

Corresponding author



Jessica K. Stewart
University of North Carolina
School of Medicine, NC, USA



Paper

Initial experience with HydroPearl microspheres for uterine artery embolization for the treatment of symptomatic uterine fibroids

What is your article about?

Stewart: Our article reports our initial experience with using Hydropearl Microspheres (Terumo Interventional Systems) for uterine artery embolisation (UAE) for patients with symptomatic uterine fibroids. Although this embolic agent is approved for UAE and other embolisation procedures, no clinical data on Hydropearl Microspheres for this indication had previously been published in the literature.

One of the foundations of IR growth is the dissemination of new technologies and short communications. Do you think there are enough IR journals for case reports, short communications, etc.?

Stewart: As interventional radiology continues to develop as an independent medical specialty, the focus of research in the specialty should, appropriately, be on publishing high-quality, prospective clinical trials. However, there is still a need for publication of brief communications to describe unique cases or novel techniques. More publication options for these types of reports would be beneficial to both investigators and members of the IR community.

What is your experience with open access journals in general? How was it with CVIR Endovascular?

Stewart: In my experience, open access journals are an excellent option for the publication of brief communications. Compared to other open access journals I have published with, I found the experience with CVIR Endovascular to be seamless, allowing our work to be available to readers in a timely fashion.

How do you think that CVIR Endovascular can assist young scientists?

Stewart: CVIR Endovascular can assist young scientists by quickly publishing their first articles. Young investigators can benefit from the seamless editorial process. Quick and easy publishing of results in CVIR Endovascular could also be advantageous for publishing preliminary data for young investigators pursuing grant funding.

Would you consider submitting to CVIR Endovascular again and if so, why?

A: Yes, I would certainly submit my work to CVIR Endovascular again. The wide number of types of articles accepted and ease of the publication process make it an appealing choice.

Visit us at cvirendovascular.org

Let's krok about it!

Let's krok about it! is a new video interview series featuring Miltiadis Krokidis, CVIR Editor and Advisor for Public Affairs, looking in depth at interesting articles published by the journal on topics ranging from ethics and consent to artificial intelligence, paediatric care, and some of the biggest studies going on in the field today.

Authors interviewed have come from all over the world and from various research backgrounds, reflecting the international scope of CVIR and the field of interventional radiology as a whole. The first video on ethics in IR just premiered in time for CIRSE 2022, but watch out in October for the next video, as we unveil a new video every month. The videos will be shared on the CVIR social media feeds as well as the CVIR playlist on CIRSE's YouTube channel.

Do you want to discuss the trending topics in IR, get to know CVIR's authors and editors, and get the inside scoop on the latest articles? Then let's krok about it!

Scan here to visit the CVIR playlist on YouTube!



Follow us on social media!



CVIR special sections

The CVIR special sections are collections of articles commissioned by a guest editor and written by renowned authors on trending IR topics. Due to popular demand, CVIR has increased its number of special sections from one per year in 2019 to two annual special editions in 2022.



The first special section this year was dedicated to TIPS and curated by Dr. Tiago Bilhim (Lisbon/PT).

The collection of articles covered one of the most challenging interventional radiology procedures i.e., transjugular intrahepatic portosystemic shunt (TIPS), which were written by renowned international voices in the field, including

In case you missed it, you can check it out by scanning this code!



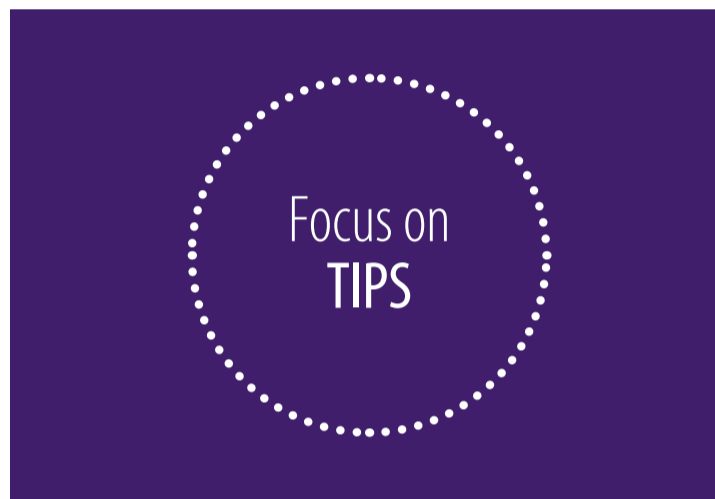
CVIR



The second special section for 2022 is currently under production and will cover radioembolisation.



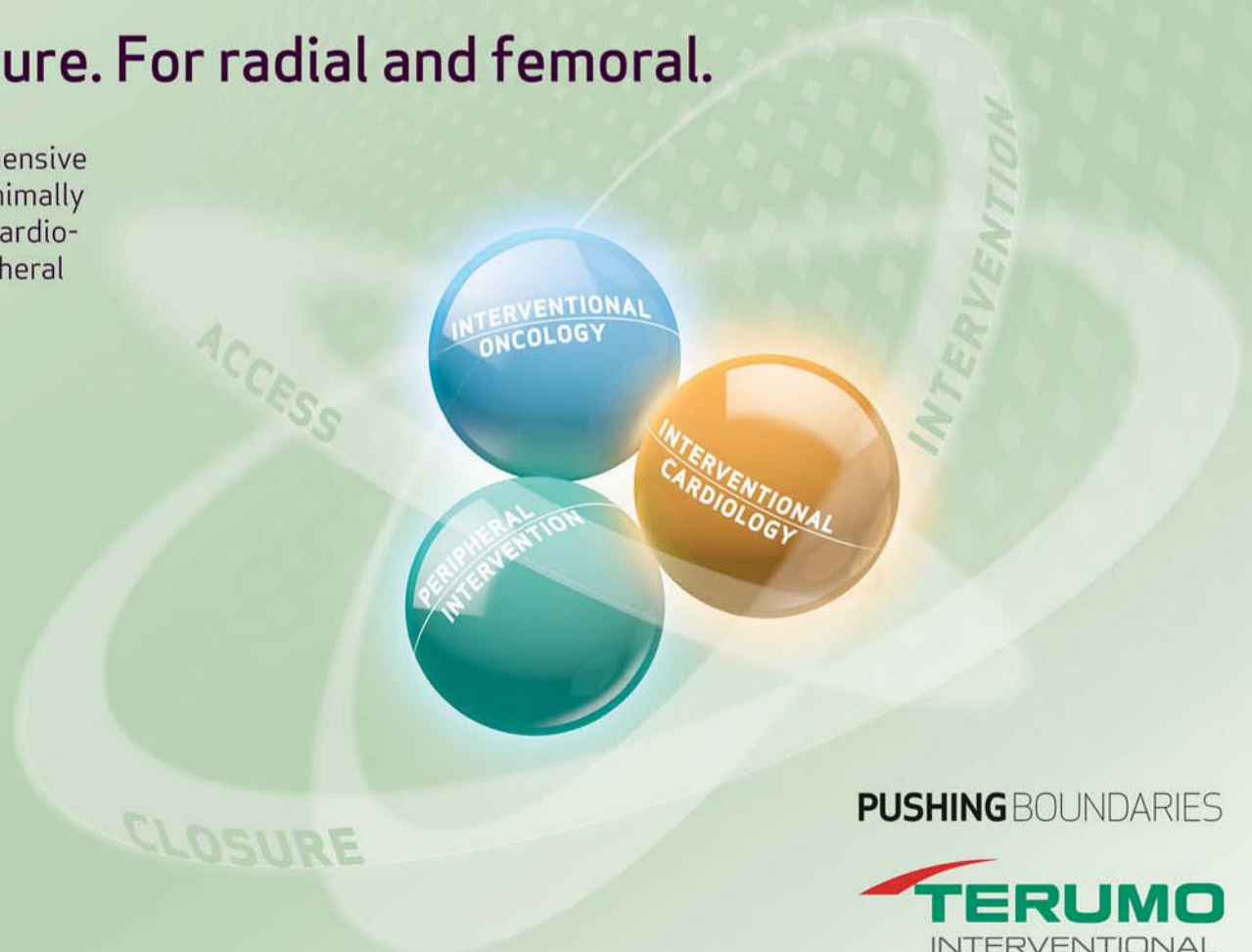Guest editors Prof. Laura Crocetti (Pisa/IT) and Prof. Thierry de Baere (Villejuif/FR) will cover everything there is to know about TARE, so make sure to check it out this fall!



INTERVENTION IN ALL DIMENSIONS

From access to closure. For radial and femoral.

Your preferred way: we offer a comprehensive portfolio spanning all dimensions of minimally invasive solutions from interventional cardiology to interventional oncology to peripheral procedures.



PUSHING BOUNDARIES



85738680718M/110716E

Don't miss this!**Students' Quiz**

Tuesday, September 13, 12:30-14:00
Foyer Diagonal

STUDENT CORNER

The ETF in the spotlight Evelin Claus – Women in IR



Evelin Claus
Universitair Ziekenhuis
Leuven/BE
ETF Subcommittee
member

because of the work-life balance, radiation exposure and a work force deficit that emerges as our field expands. However, pregnancy-related concerns may rise only to female IRs as this leads to a gap in our training for at least a year when it comes to procedures where radiation is involved.

Is it hard to balance work and the private life as an IR?

Claus: Balancing work and private life can be challenging, but I don't think it is necessarily more challenging compared to our surgical colleagues. Maintaining a good work-life balance is manageable as long as you have a good team to carry the load together. With your colleagues, you should have a fair distribution of the 'on call' days and a good mutual understanding. The key to maintaining a good work-life balance is setting your own boundaries and priorities, as there are only 24 hours in a day.

Your recommendations or suggestions to young women who would like to pursue a career in IR?

Claus: My recommendation is to stay focused and to make sure that you have had enough education and a broad experience before you start working somewhere definitively. Ideally, 2 years of overall experience in at least two centres should be adequate to start with enough self-confidence. Always try to learn on a daily basis, even if there are just 'routine' cases scheduled that day. Be prepared that obtaining knowledge and experience will never stop during your professional career.

Why did you choose a career in IR?

Claus: Interventional radiology is a very diverse field with a wide variety of pathologies and procedural techniques. This makes it possible to perform a different set of procedures (venous, arterial, oncologic etcetera) on the same day. Because of this, it is a very challenging, but ultimately rewarding field. You never get bored. With the technical evolution and the materials we use, we can always push the boundaries of what's possible and strive to have the best results for our patients. It allows to perform new and innovative procedures, as well as out-of-the-box thinking about new applications for these new techniques. For me, this diversity and always striving for excellence in what we do, is what daily motivates me to give everything.

Are women generally hesitant to follow a career in interventional radiology? (Why or why not?)

Claus: In general, most challenges related to pursuing a career in interventional radiology, are not gender related. Both men and women may be hesitant to choosing IR as a career

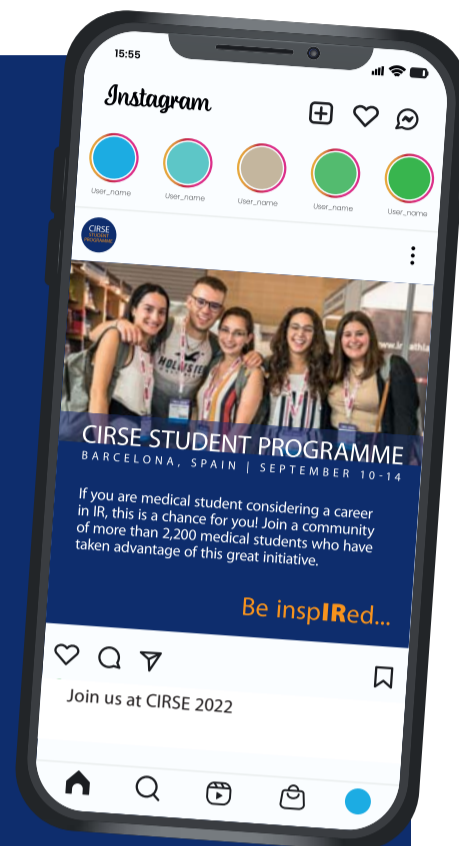**DAILY APP QUIZ**

Don't forget to answer the daily students quiz in the CIRSE app!

The first participant answering all questions correctly wins a ticket for the CIRSE Farewell Party!

Stay up-to-date on IR even after the congress is over!

Stay connected with the CIRSE students community by following the CIRSE Student Programme on Facebook and Instagram!



Recommended sessions of the day

Obstetric haemorrhage
08:30-09:30, Room 117

Treating the dysfunctional vascular access: treatment area-based approach
08:30-09:30, Room 116

Embolisation for life-threatening haemorrhage
10:00-11:00, Room 116

Embolisation in non-traumatic benign vascular diseases
11:30-12:30, Room 112

Embolisation in bleeding: which material for which lesion
16:15-17:15, Room 114

Hands-on device and simulation training sessions of the day

Prostatic artery embolisation: basics, current role and future perspectives
17:00-18:00, Simulator Gallery


ETF Short Talks

ETF Short Talks: How to boost your IR career
15:00-16:00, News on Stage

IR Congress News is published as an additional source of information for all CIRSE 2022 participants. The articles and advertorials in this newspaper reflect the authors' opinions. CIRSE does not accept any responsibility regarding their content.

Managing Editor: Petra Mann
Editorial Team: CIRSE Communications Department (communications@cirse.org)
Graphics/Artwork: LOOP. ENTERPRISES media / www.loop-enterprises.com

Students in the Spotlight



Eric Cyphers
Morsani College of Medicine
Florida/US

CIRSE: Can you tell us about yourself and why you decided to study medicine?

Cyphers: I am originally from Philadelphia, USA and recently completed my 3rd year of medical school at the Philadelphia College of Osteopathic Medicine. Currently, I am taking a year away from medical school to complete a Masters of Bioethics at Columbia University in New York. I decided to study medicine because of the service oriented and patient-centred aspects at its heart. Medicine offers a special and fulfilling pathway to help and heal others via specialised knowledge and good intentions. I think there is no greater good to devote oneself to.

CIRSE: How did you hear about CIRSE?

Cyphers: CIRSE has a reputation in American for always being on the forefront of medical science.

CIRSE: What do you think is the best feature about the CIRSE Student Programme?

Cyphers: Students are given a platform to share their work and learn from other students globally. CIRSE students are the future leaders of interventional medicine, so the support we get today is invaluable.

CIRSE: What are your next steps?

Cyphers: I plan to become an interventional radiologist. Still deciding which pathways to take to reach this goal.

DON'T MISS THIS!

Students' Quiz

Tuesday, September 13, 12:30-14:00, Foyer Diagonal



OBTAIN YOUR CERTIFICATE OF ATTENDANCE!

Fill out the evaluation form on our website to obtain your certificate!



Traditional Catalan Cuisine

Katie Stamerjohn
CIRSE Communications Department

After a full day of attending sessions and interacting with colleagues, you should take time to enjoy the world-class culinary scene of Barcelona! While visitors already know famous Spanish dishes such as paella or churros, those are not traditional Catalan. Catalan cuisine focuses on high-quality ingredients found along the Mediterranean coast to make simple yet flavourful dishes.

Pa amb tomàquet

This simple recipe is a staple in any bar and restaurant in Barcelona; it consists tomato rubbed on bread, topped with salt and olive oil. The first written record of this dish dates back to 1884, when old stale bread was spread with tomato and olive oil to soften it. Authentic pa amb tomàquet will use a sourdough loaf called pa de pagès.

Escalivada

Escalivada is another well-loved Catalan dish, also known for its simple ingredients. Typically, this dish is made with aubergine, tomato and red pepper, but other vegetables can also be used. The name of the dish derives from the Catalan word *escalivar*, meaning "to cook on hot embers," which gives the vegetables their characteristic smoky flavour. The vegetables are traditionally grilled whole, often directly over hot embers, then peeled, seeded and served. It can be served as a warm salad on its own or as a side dish.

Calçots

A cross between a spring onion and a leek, calçots are in season in winter and early spring. The calçot is grilled directly on the fire. Afterwards, its outermost layer is peeled and it is served with a Romesco sauce. The process is so messy that many restaurants provide bibs and gloves to prevent their patron's clothes from staining. Nevertheless, the vegetable is so popular, that there is a word (*calçotada*) to describe the gathering of friends and family with the sole purpose of eating calçots.



Calçots: fun to eat, but maybe not ideal for a first date.

Crema cremada

This custard dessert is similar to *crème brûlée*, but uses milk instead of cream along with citrus and cinnamon flavours. Crema Catalana's history can be traced back to the Middle Ages and is extensively described in the region's literature. The 14th-century cookbook *Llibre de Sent Soví* is where it was first mentioned. Crema Catalana is older than its French cousin, as *crème brûlée* didn't appear until the 17th century.

Arròs negre

A popular rice dish originating from Catalonia and Valencia, *arròs negre* certainly stands out due to its black colour which does not derive from black rice, but squid ink used to enhance the dish's rich seafood flavour. Ingredients of *arròs negre* include squid or cuttlefish, white rice, squid ink, green cubanelle peppers, olive oil, and seafood broth. It is usually served with *allioli*.

Bombes

Bombes are a deep-fried mix of mashed potatoes and minced meat, topped with *allioli* and a spicy cayenne sauce. This tapas dish was created during the turmoil in Catalonia in the early 1900s. Anarchists and regional-national groups bombed the neighbourhood of Barceloneta with small round iron balls filled with explosives and lit by a string fuse.

In this neighbourhood, the bar owner Maria Pla created a dish to represent the bombs and make light of her harsh reality. Even the spicy red sauce was to resemble the bloodshed in the area.

Porró

Drinking from a *porró* is a fun Catalan tradition every visitor should try at least once. This traditional wine pitcher made of glass features a long spout which enables its users to pour the wine into their mouth from a distance, allowing a group of people to share the same drink without touching it with their lips. It takes some practice to get the hang of it, so make sure to use a bib the first time you try!



Drinking from a porró: one of the few things you get better at as you keep drinking.

CIRSE library

Access the CIRSE Library for a wealth of IR knowledge:

- 22 congresses including CIRSE, ECIO, ET and IROS
- 19 webinars and many more on the way
- Over 11,000 lectures and posters
- Over 4,000 speakers from around the world
- 8 main topics covering the whole spectrum of IR

Get access to IR's top educational content and stay up to date with monthly **topic packages** curated by leading experts, the new CIRSE Library exclusive content "Highlights in IR", bi-weekly featured content, **EBIR preparation** material and more!

CIRSE Members have free access!

Join now or purchase your Digital All-Access Pass to stay up-to-date with all the latest in the world of IR.

The image displays three overlapping screenshots of the CIRSE Library website. The top screenshot shows the main navigation bar with a search bar and menu items like 'Congresses', 'Webinars', 'Topics', 'Next Generation', 'Industry Spotlights', 'Topic Packages', 'EBIR Preparation', and 'Library Access'. The middle screenshot shows a search result for 'CIRSE 2021 Summit' with a sidebar menu listing 'MAIN TOPIC' (Aortic Intervention, Arterial Intervention, Embolisation, IR Management, Interventional Oncology, Neurointervention, Non-Vascular Intervention, Venous Intervention), 'SUBTOPIC', 'LECTURE' (Invited, Submitted, Industry), and 'POSTER' (Scientific, Educational, Case Report). The main content area displays a grid of lecture cards with titles like 'EVAR', 'Daily wrap-up', 'Combined treatment', 'The management of peri- and postprocedural pain in IR: unmet needs', 'Endovascular goes radial', and 'Embolisation'. The bottom screenshot shows a 'Topic Package' for 'ECIO 2022' with a list of compiled and regularly updated individual, topic-focused guidelines, including 'Immunotherapy and...', 'Kidney tumours', 'Image-guided biop...', and 'Venous access'.

library.cirse.org